

The use of Ber-EP4 antigen in the differential diagnosis of basosquamous carcinoma from squamous and basal cell carcinoma

Bazoskuamöz karsinomun skuamöz ve bazal hücreli karsinomdan ayırıcı tanısında Ber-EP4 antijeninin kullanımı

Nermin KARAHAN¹, Şirin BAŞPINAR², Mehmet YILDIRIM³, İbrahim BARUT⁴

Department of Pathology, Suleyman Demirel University School of Medicine¹, Department of Pathology, Egirdir Bone Joint Diseases Treatment and Rehabilitation Hospital², Department of Dermatology, Suleyman Demirel University School of Medicine³, Department of Surgery, Suleyman Demirel University School of Medicine⁴, ISPARTA

ABSTRACT

Basal cell and squamous cell carcinoma of skin are common tumors which can be easily distinguished on hematoxylin and eosin stained sections, but basosquamous carcinoma is a controversial entity. The aim of our study was to distinguish basal cell carcinoma and basosquamous carcinoma using Ber-EP4, immunohistochemically in 52 skin tumors. Twenty basal cell carcinomas, 20 squamous cell carcinomas, 10 basosquamous carcinomas and 2 collision tumors of the skin were stained with Ber-EP4 immunohistochemically. All basal cell carcinomas were stained strongly and diffusely with Ber-EP4, whereas squamous cell carcinomas were not, and basosquamous carcinomas were partially stained. Our results suggest that, distinction of basal cell carcinoma and basosquamous carcinoma can be achieved with routine immunohistochemical Ber-EP4 staining.

Key words: Ber-EP4, basal cell carcinoma, basosquamous carcinoma, squamous cell carcinoma

ÖZET

Derinin bazal hücreli ve skuamöz hücreli karsinomu hematoxilen-eozin boyalı kesitlerde kolaylıkla ayrılabilen tümörlerken, bazoskuamöz karsinom tartışılabilir bir antitedir. Çalışmamızın amacı 52 deri tümöründe immünhistokimyasal olarak Ber-EP4 kullanılarak bazal hücreli karsinom ve bazoskuamöz karsinom ayrımını yapmaktır. Derinin 20 bazal hücreli karsinomu, 20 skuamöz hücreli karsinomu, 10 bazoskuamöz karsinomu ve 2 kollüzyon tümörü immünhistokimyasal olarak Ber-EP4 ile boyandı. Bazal hücreli karsinomların tümü Ber-EP4 ile güçlü ve diffüz olarak boyanırken, skuamöz hücreli karsinomlarda boyanma izlenmedi. Bazoskuamöz karsinomlar ise parsiyel boyandı. Sonuçlarımız bazal hücreli karsinom ve bazoskuamöz karsinom ayrımının rutin immünhistokimyasal Ber-EP4 boyanması ile gerçekleştirilebileceğini öne sürmektedir.

Anahtar sözcükler: Ber-EP4, bazal hücreli karsinom, bazoskuamöz karsinom, skuamöz hücreli karsinom

INTRODUCTION

Basal cell carcinoma and squamous cell carcinoma of the skin are common tumors which can usually be distinguished on hematoxylin and eosin stained sections. Basosquamous carcinoma is a more controversial entity with

hout a well established phenotype (1,2). Accurate tumor typing has important implications to the patient since these tumors have different modes of behavior and metastatic potential (3,4).

In some cases distinction between a basal and squamous cell carcinoma can be difficult and definitive identification of a basosquamous carcinoma is more problematic (5). Several studies have attempted to address some of these issues using immunohistochemistry, but they ha-

Corresponding Author: Nermin Karahan, MD
Süleyman Demirel Üniversitesi Tıp Fakültesi, Patoloji Anabilim Dalı 32900 Isparta- Turkey

ve not been fully resolved (4-6).

Ber-EP4 is a monoclonal antibody prepared from human breast adenocarcinoma cell line (MCF-7). The monoclonal antibody recognizes 34 kDa and 39 kDa noncovalently linked glycopeptides found mostly on human epithelial cells. The function of the glycopolypeptide antigen that is recognized by Ber-EP4 remains unknown (7,8).

Ber-EP4 reactivity has been examined in a wide range of normal and neoplastic human tissues. This antibody reacts with most carcinomas of various origin, including those of breast (9), esophagus (10), stomach (11), colon (12), rectum (12), pancreas (11), kidney (13), liver (7), lung (14), thyroid gland (7), salivary gland (7), vagina (8), ovary (15), cervix uteri (8), and nonneoplastic epithelial cells, except adult hepatocytes and parietal cells (8). In diagnostic pathology, Ber-EP4 has been suggested to distinguish carcinoma from mesothelioma (16,17).

Interestingly, Ber-EP4 antigen was not detected in either normal keratinocytes or squamous cell carcinoma of the skin (18). However, in the skin it can distinguish basal cell carcinoma from squamous cell carcinoma (5,6).

Basal cell carcinoma can be easily distinguished from squamous cell carcinoma by routine hematoxylin and eosin (HE) staining. However, the distinction of basosquamous carcinoma from keratotic basal cell carcinoma and squamous cell carcinoma is not always easy. Each tumor has different metastatic capability and therefore the prognosis for each tumor differs from each other (2,5,19-21). Our aim in this study is to show that the use of Ber-EP4 antigen in the distinction of basosquamous carcinoma from squamous cell carcinoma and basal cell carcinoma facilitates the establishment of accurate diagnosis which is important in determining further prognosis of the patient.

MATERIALS and METHODS

Twenty basal cell, 10 basosquamous cell, 20 squamous cell carcinomas and 2 collision tumors were retrospectively retrieved from the archival material of the Suleyman Demirel University Medical School Department of Pathology. Collision tumors have areas of true basal cell carcinoma alongside distinct squamous cell carcinoma, with either a narrow tumor-free zone or an abrupt transition. These were considered as separate carcinomas and not included in the basosquamous group. All HE stained slides were reviewed. Immunohistochemical staining was performed on selected blocks. Light microscopic examination and immunohistochemical evaluation were independently performed. Immunohistochemical analysis for Ber-EP4 was performed on formalin-fixed, paraffin-embedded archival tissue using the streptavidin-biotin-peroxidase technique. For all cases, 4 µm histologic sections were deparaffinized in xylene and dehydrated in descending dilutions of ethanol. For the antigen retrieval, slides were treated by microwave heating in citrate buffer (pH 6.0) for 10 minutes. Endogenous peroxidase activity was blocked by 20 minutes of incubation with 0.3% hydrogen peroxidase. Pepsin incubation was performed at 37°C, for 15 minutes. Slides were tested with mouse monoclonal anti Ber-EP4 antibody (dilution: 1/20, Clone: Epithelial Specific Antigen Ab-9, Neomarkers). Sections were tested with a streptavidin-biotin-peroxidase kit (Ultra Vision Large Volume Detection System Anti-polyvalent, HRP, LabVision, Corporation 47790 Westinghouse Dr. Fremont, Ca USA), and after incubation the reaction product was detected using diaminobenzidine (DAB). Finally, the sections were counterstained with Mayer's hematoxyline, and mounted with aqueous mounting medium. Only membranous staining was accepted as specific (7).

RESULTS

The patients with basal cell carcinoma (12 males and 8 females) were between 37 and 73 years of age, (mean age 58). In 14 patients, tumors were located on head and neck whereas in the remaining patients on the trunk, limb or other sites.

Mean age of patients (7 males and 3 females) with squamous cell carcinoma was 84 years (range: 72-91 years). Fourteen of these were located on head and neck, the remainder were on the trunk, and limbs. All squamous cell carcinomas were well or moderately differentiated except for one poorly differentiated tumor.

The patients with basosquamous cell carcinomas (8 males and 2 females) were between 45 and 78 years of age (mean age 52 years). All basosquamous cell carcinomas were located on head and neck.

Two collision tumors were located on head and neck, and patients were 42 and 65 year-old females.

All 20 of basal cell carcinomas were successfully stained with Ber-EP4. Each basal cell carcinoma showed strong and diffuse positive staining with Ber-EP4 (20/20 cases) which was membranous (Figures 1 and 2). In two keratotic basal cell carcinomas, we detected diffuse positive membranous staining except in keratinized foci. In contrast, squamous cell carcinomas and

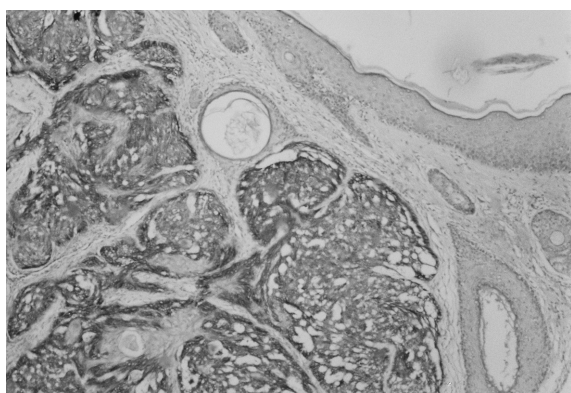


Figure 1. Basal cell carcinoma showing strong membranous positive staining with Ber-EP4. The overlying squamous epithelium was not stained (x40).

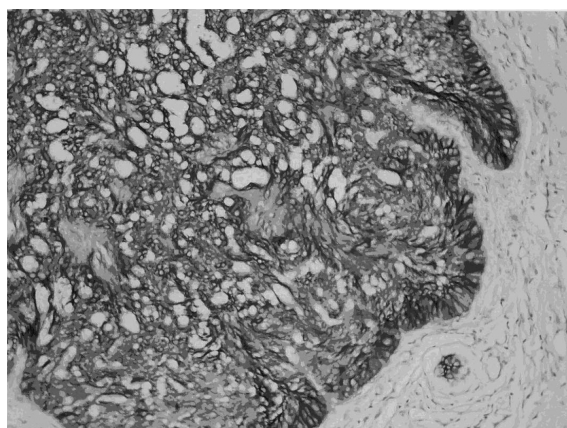


Figure 2. Ber-EP4 showing strong membranous positivity in basal cell carcinoma (x100).

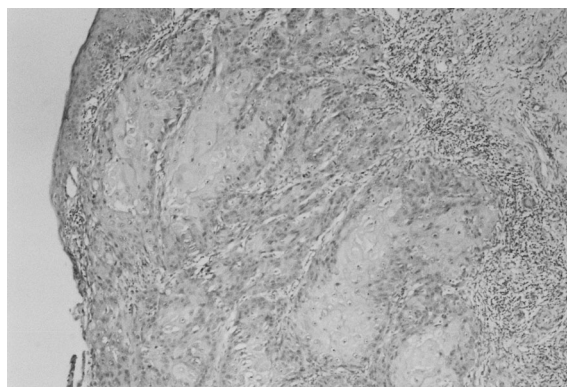


Figure 3. Squamous cell carcinomas were not stained with Ber-EP4 antibody (x40).

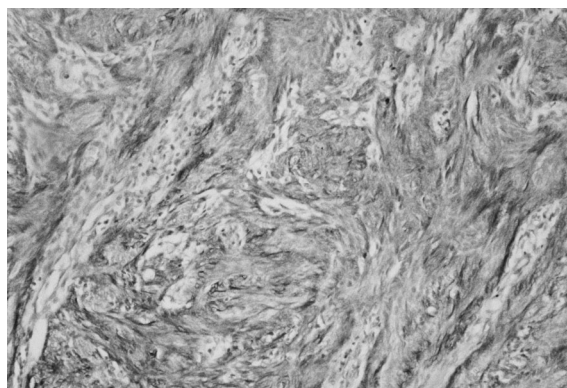


Figure 4. Basosquamous carcinomas were stained partially with Ber-EP4. Staining was patchy within the tumor (x40).

surface squamous epithelium were not stained (0 / 20) (Figure 3). Ten basosquamous cell carcinomas were stained partially with Ber-EP4. Staining was often patchy within the tumor (Figure 4). Two collision tumors included in the

study showed a sharp cut-off in immunostaining between the areas of basal and squamous cell carcinomas. In these tumors areas of basal cell carcinomas were stained strongly, whereas areas with squamous cell carcinoma were not stained.

DISCUSSION

The importance of distinguishing basosquamous carcinoma from basal cell carcinoma or squamous cell carcinoma lies in their significantly greater propensity to metastasize to distant sites (20).

In the skin, Ber-EP4 immunoreactivity has been reported to be localized in the structures composed of basaloid epithelial cells, fetal epithelial germ cells, basal cell carcinomas and trichoepitheliomas as well as eccrine or apocrine ducts. Ber-EP4 stains adnexal epithelium, but not keratinocytes (18).

Tellechea et al (6) have showed that Ber-EP4 has diagnostic applications in skin malignancies, as it labels all basal cell carcinomas as opposed to squamous cell carcinomas. They thought that Ber-EP4 could serve as a definitive marker for basal cell carcinoma. Also Kist et al. (22) found Ber-EP4 as a useful and reliable marker for basal cell carcinoma. They concluded that this antibody helps to locate latent basal cell carcinoma in inflammatory Mohs margins.

Our study shows that immunohistochemistry for Ber-EP4 helps to distinguish basosquamous cell carcinoma from basal cell and squamous cell carcinoma. Each basal cell carcinoma showed strong positive staining with Ber-EP4. In contrast, none of the squamous cell carcinomas were stained. We found that basosquamous cell carcinomas have areas staining like those of basal and squamous cell carcinoma.

Beer TW et al (19) studied 75 skin tumors to investigate the diagnostic value of Ber-EP4 and epithelial membran antigen (EMA) staining in differentiating basal, squamous and basosquamous cell carcinomas of the skin. Similar results have been reported by them. They conclu-

ded that basosquamous cell carcinomas have an immunoprofile similar to basal cell carcinomas and immunohistochemistry allows their distinction from squamous cell carcinomas. They proposed that the term basosquamous carcinoma should be applied to tumors resembling basal cell carcinoma that have areas of squamoid differentiation showing positive staining for Ber-EP4 with negative staining for EMA. It was suggested that these two immunostaining techniques increase the level of diagnostic certainty. Our results also showed that identification of basosquamous cell carcinoma is facilitated using Ber-EP4 staining.

In summary, Ber-EP4 helps to distinguish basosquamous carcinomas from basal and squamous cell carcinomas. Distinction of these entities has great clinical relevance since basal cell carcinoma very rarely metastasizes and may be treated with local radiotherapy, whereas basosquamous and squamous cell carcinoma have a distinct risk of metastasis, and radiotherapy may be inappropriate.

REFERENCES

1. Bowman PH, Ratz JL, Knoepf TG, Barnes CJ, Finley EM. Basosquamous carcinoma. *Dermatol Surg* 2003;29:830-833.
2. Martin RCG, Edwards MJ, Cawte TG, Sewell CL, McMasters KM. Basosquamous carcinoma: analysis of prognostic factors influencing recurrence. *Cancer* 2000;88:1365-1369.
3. Cannon CR, Hayne S. Basosquamous carcinoma of the head and neck. *Ear Nose Throat J* 1990;69:822-825.
4. Saladi RN, Singh F, Wei H, Lebwohl MG, Phelps RG. Use of Ber-EP4 protein in recurrent metastatic basal cell carcinoma: a case report and review of the literature. *Int J Dermatol* 2004;43:600-603.
5. Jones MS, Helm KF, Maloney ME. The immunohistochemical characteristics of the basosquamous cell carcinoma. *Dermatol Surg* 1997;23:181-184.
6. Tellechea O, Reis JP, Domingues JC, Poiars Baptista A. Monoclonal antibody Ber EP4 distinguishes basal cell carcinoma from squamous-cell carcinoma of the skin. *Am J Dermatopathol* 1993;15:452-455.
7. Momburg F, Moldenhauer G, Hammerling GJ, Moller P. Immunohistochemical study of the expression of a Mw 34000 human epithelium-specific surface glycoprotein in normal and malignant tissue. *Cancer Res* 1987;47:2883-2891.
8. Moldenhauer G, Momburg F, Moller P, Schwartz R, Hammerling GJ. Epithelium-specific surface glycopro-

- tein of Mr 34000 is a widely distributed human carcinoma marker. *Br J Cancer* 1987;56:714-721.
9. Kasimir-Bauer S, Oberhoff C, Schindler AE, Seeber S. A summary of two clinical studies on tumor cell dissemination in primary and metastatic breast cancer: methods, prognostic significance and implication for alternative treatment protocols *Int J Oncol* 2002;20:1027-1034.
10. Stoecklein NH, Siegmund A, Scheunemann P, Luebke AM, Erbersdobler A, Verde PE, et al. Ep-CAM expression in squamous cell carcinoma of the esophagus: a potential therapeutic target and prognostic marker. *BMC Cancer* 2006;6:165.
11. Gaffey MJ, Mills SE, Swanson PE, Zarbo RJ, Shah AR, Wick MR. Immunoreactivity for BER-EP4 in adenocarcinomas, adenomatoid tumors, and malignant mesotheliomas. *Am J Surg Pathol* 1992;16:593-599.
12. Denis MG, Lipart C, Leborgne J, LeHur PA, Galmiche JP, Denis M, et al. Detection of disseminated tumor cells in peripheral blood of colorectal cancer patients. *Int J Cancer* 1997;74:540-544.
13. Pan CC, Chen PC, Ho DM. The diagnostic utility of MOC31, BerEP4, RCC marker and CD10 in the classification of renal cell carcinoma and renal oncocytoma: an immunohistochemical analysis of 328 cases. *Histopathology* 2004;45:452-459.
14. Brezicka T. Expression of epithelial-cell adhesion molecule (Ep-CAM) in small cell lung cancer as defined by monoclonal antibodies 17-1A and BerEP4. *Acta Oncol* 2005;44:723-727.
15. Georgescu CV, Florescu M, Simionescu C. Value of immunohistochemistry in confirming undifferentiated ovarian carcinomas. *Rom J Morphol Embryol* 2004;45:133-142.
16. Latza U, Niedobitek G, Schwarting R, Nekarda H, Stein H. Ber-EP4: new monoclonal antibody which distinguishes epithelia from mesothelial. *J Clin Pathol* 1990;43:213-219.
17. Sheibani K, Shin SS, Kezirian J, Weiss LM. Ber-EP4 antibody as a discriminant in the differential diagnosis of malignant mesothelioma versus adenocarcinoma. *Am J Surg Pathol* 1991;15:779-784.
18. Ozawa M, Aiba S, Kurasawa M, Tagami H. Ber-EP4 antigen is a marker for a cell population related to the secondary hair germ. *Exp Dermatol* 2004;13:401-405.
19. Beer TW, Shepherd P, Theaker JM. Ber EP4 and epithelial membrane antigen aid distinction of basal cell, squamous cell and basosquamous carcinomas of the skin. *Histopathology* 2000;37:218-223.
20. Lopes de Faria J, Nunes PH. Basosquamous cell carcinoma of the skin with metastases. *Histopathology* 1988;12:85-94.
21. Maloney ML. What is basosquamous carcinoma. *Dermatol Surg* 2000; 26:505-506.
22. Kist D, Perkins W, Christ S, Zachary CB. Anti-Human Epithelial Antigen (Ber-EP4) helps define basal cell carcinoma masked by inflammation. *Dermatol Surg* 1997;23:1067-1070.