

An unexpected diagnosis during laryngeal intubation: osseous polypoid lesion of the tongue: osteoma or choristoma?

Laringeal entübasyon sırasında tesadüfi tanı: lingual osseöz polipoid lezyon: osteom veya koristom?

Ertap AKOĞLU¹, Esin ATİK², Sinem KARAZİNCİ³, Şemsettin OKUYUCU¹, Çağla ÖZBAKİŞ⁴, Ali BALCI³, Ramazan GÜMÜŞ¹, Şafak DAĞLI¹

Mustafa Kemal University Tayfur Ata Sokmen School of Medicine, Departments of Otolaryngology Head and Neck Surgery¹, Pathology², Radiology³, and Anesthesiology and Reanimation⁴, HATAY

ABSTRACT

Soft tissue osteoma is a rare entity having a strong predilection for the head and neck region, mainly posterior region of the tongue. The so-called lingual osteoma is mostly manifested as an asymptomatic exophytic lesion. It can be diagnosed by physical or radiological examinations.

We represent a patient with undiagnosed lingual osteoma, accidentally detected during laryngoscopy for intubation for a gynecologic surgery. General anesthesia was planned for a 52 year-old undergoing gynecologic surgery. Before surgery a laryngoscopy was performed for intubation. During this procedure a pedunculated mass was seen in the posterior region of the tongue. Although the pathogenesis and terminology is controversial, surgical excision is the preferred treatment modality. We aimed to present an osseous lesion in tongue, to review the literature in regard to relevant clinical, histological features and to discuss the pathogenesis and terminology involved.

Key words: Tongue, osteoma, intubation

ÖZET

Yumuşak doku osteomu ender bir durum olup, başlıca dilin arka kısmı olmak üzere baş-boyun bölgesinde görülmeye güçlü bir yatkınlık gösterir. Lingual osteom adı verilen bu durum sıklıkla yakınmasız dışa doğru gelişmiş bir lezyon olarak görülür. Tanısı fizik muayene ya da görüntüleme yöntemleriyle konur.

Sunduğumuz hasta daha önce tanı almamış, jinekolojik ameliyat öncesi entübasyon sırasında tesadüfen fark edilen bir lingual osteom olgusudur. Elli iki yaşında kadın hastanın jinekolojik cerrahi için genel anestezi alması planlanmıştır. Cerrahi öncesi entübasyon için laringoskopi yapılması esnasında dilin arka kısmında saph bir kitle görülmüştür. Patogenez ve terminoloji konusu tartışılmalı olsa da, tedavi yönteminde seçim cerrahidir. Bu makaledeki amacımız dildeki kemiksi bir lezyonu sunarken, klinik ve histolojik özellikleri dikkate olarak literatürü gözden geçirmek ve patogeneze birlikte terminolojiyi tartışmaktır.

Anahtar sözcükler: Dil, osteom, entübasyon

INTRODUCTION

Extrasosseous osteoma in the tongue is a rare entity with a typical location in the posterior third close to foramen caecum and posterior to circumvallate papillae but it also can be located in the lateral margins and in the mid-third of the

tongue. It can be pedunculated or sessile (1). The patients are usually young women having a hard mass arising from posterior part of the tongue with no symptoms. Difficulty in swallowing is the most common complaint in symptomatic cases. Osteomas are two to three times more prevalent in women than in men (1,2,3). Although reports about patients having lingual osteomas at the time of birth and in early childhood

Corresponding author: Şemsettin Okuyucu, Mustafa Kemal Üniversitesi Araştırma Hastanesi 31100, Antakya, Hatay

have been cited in literature, the average age range is the third and fourth decades (4). The pathogenesis and terminology of the lesion remains uncertain (3,4). According to our knowledge this is the first case that probable diagnosis is established during intubation.

CASE REPORT

General anesthesia was planned for a 52 year-old undergoing gynecologic surgery. Before surgery a laryngoscopy was performed for intubation. During this procedure a pedunculated mass was seen in the posterior region of the tongue that didn't restrict intubation. After the patient had recovered from her gynecologic complaints, a physical examination was made by an otolaryngologist. The patient was aware of this mass with no symptoms so the duration of the lesion is unknown. Examination showed a 4x2x2 cm firm bony hard swelling with a normal color and aspect with the overlying mucosa pedunculated to the dorsum of the tongue just left to the foramen caecum (Figure 1). Computerized tomographic (CT) scans revealed a dense lesion consisting of hypodense areas with a well-demarcated border at the base of the tongue (Figure 2). She underwent a surgical excision under general anesthesia with a provisional

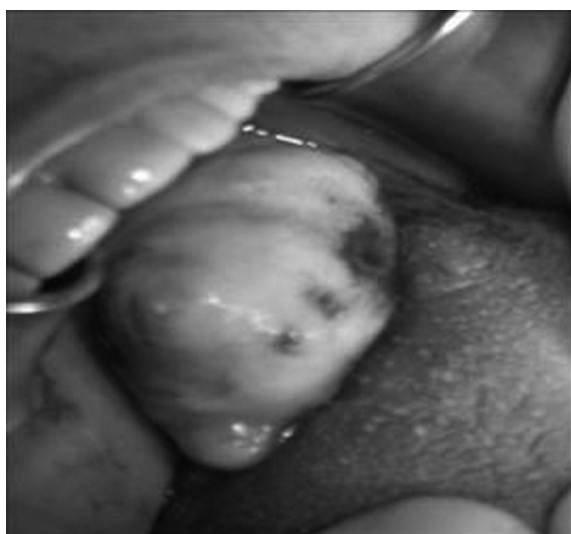

Figure 1. Lingual osteoma on the dorsum of the tongue.

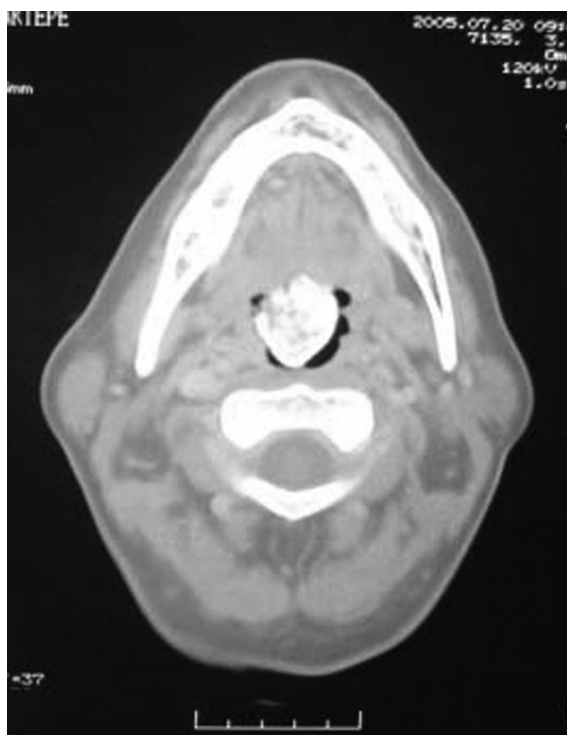

Figure 2. CT image revealed a well-demarcated hyperdense lesion with hypodense areas at the base of the tongue.

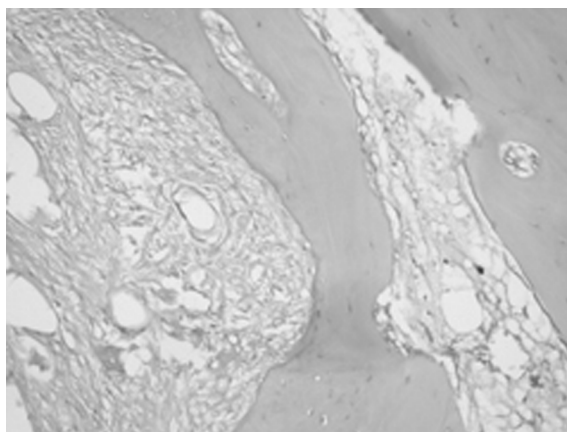


Figure 3. Dense lamellar bone including fibroadipose tissue with rare osteoblasts (HE x400).

diagnosis of osteoma.

Macroscopic examination showed a yellow-beige colored, polypoid osseous mass measuring 4x2x2 cm. After decalcification, the samples underwent routine tissue processing and the paraffin blocks were prepared. Five micron sections retrieved from the paraffin blocks stained with hematoxylin eosin were examined under light microscope.

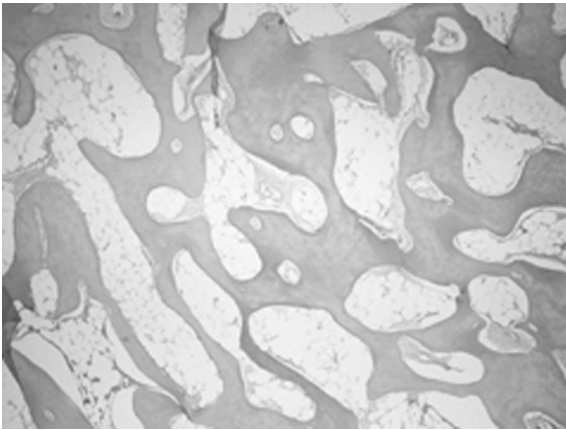


Figure 4. Dense lamellar osteoid tissue (HE x40).

Microscopic examination revealed mostly dense lamellar osteoid tissue with rare osteoblasts, fibroadipose tissue and bone marrow (Figure 3-4).

DISCUSSION

There are different theories related to the pathogenesis of the osseous lesions of the tongue. Two main proposals are embryologic developmental malformation and reactive or posttraumatic theory. Monserrat was the first who explained the embryologic developmental theory related to osseous lesions in the tongue (3). The rationale of his theory depends on the fact that two thirds of the tongue derives and the posterior third originates from the third branchial arch. First and third branchial arches meet in the foramen caecum. It is known that bony structures such as malleus and incus develop from the first and hyoid bone from the third branchial arch through enchondral ossification. Therefore, these branchial arches have the capability to to enclose mesenchymal pluripotent cells for the subsequent development of an osseous lesion in the tongue. Cataldo et al. and Jankhe and Daly have proposed an alternative developmental theory, which is associated with the remnants of thyroid tissue (5,6). In embryologic life the anlage of the thyroid gland descends from the foramen caecum to the neck. They suggested that the primordial endodermal or differentiated thyroid

parenchymal cells developing from undescended intraglossal thyroid remnants can produce unusual osseous proliferation later in life (3).

The second theory suggests that osseous lesions of the tongue represent a reactive or posttraumatic center for ossification. 'Myositis ossificans' is the term used for this kind of lesions in other muscles of the body. Chronic inflammation due to trauma or irritation is a common finding at the posterior third of the tongue. Inflammatory and posttraumatic lesions have irregular areas of ossification, with neither haversian systems nor normal bone architecture (3). Controversially osseous lesions in the tongue are composed of well-developed mature bone that could not be associated with trauma. On the other hand two cases was cited in literature that showed diffuse foci of ossification without a well-circumscribed osseous lesion (7,8). Reactive responses of the tissue to trauma and irritation may differ from chronic inflammation to metaplasia, and also osteoma which might be the most mature stage of metaplastic process (9).

Our case was reported as osteoma. Differential diagnosis includes sialolithiasis, lipoma with osseous metaplasia, osteo-cartilaginous choristoma, metastatic osteosarcoma, liposarcoma with metaplasia, and post-traumatic chondrification (9,10,11).

There is not a consensus on the terminology for these lesions. Osteoma defines a benign, progressively enlarging neoplasm of bone originating from osteogenic tissue and it is closely associated with the skeleton. Lingual osteoma doesn't fulfill these criteria because the tongue is not associated with skeleton and it is not an osteogenic tissue. "Lingual choristoma" is suggested as an alternative term because it describes a cohesive tumor like mass consisting of normal cells in an abnormal location. As some of the lesions have been reported to increase in size, the term choristoma fails to fit these definitions. Also not widely used 'osseous tumor like lesions of the tongue' is a descriptive term for this kind of lesions (12).

Even it may be asymptomatic, surgical excision is the preferred treatment modality. Histopathologic examinations are necessary for the diagnosis. After removing the lesion, recurrence is not expected.

REFERENCES

1. Bernard PJ, Shugar JMA, Mitnick R, Som PM, Meyer R. Lingual osteoma. Arch Otolaryngol Head Neck Surg 1989;115:989-990.
2. Van Der Wal N, Van Der Waal I. Osteoma or chondroma of the tongue; a clinical and postmortem study. Int J Oral Maxillofac Surg 1987;16:713-717.
3. Vered M, Lustig JP, Buchner A. Lingual osteoma: a debatable entity. J Oral Maxillofac Surg 1998;56:9-13.
4. Supiyaphun P, Sampatankul P, Kerekhanjanarong V, Chawakitchareon P, Sastarasadhith V. Lingual osseous choristoma: a study of eight cases and review of the literature. Ear Nose Throat J 1998;77(4):316-318.
5. Cataldo E, Shklar J, Meyer I. Osteoma of the tongue. Arch Otolaryngol 1967;85:202-206.
6. Jahnke V, Daly JF. Osteoma of the tongue. J Laryngol Otol 1968;82:273-275.
7. Wasserstein MH, Sunderraj M, Jain R, Yamane G, Chauderhy AP. Lingual osseous choristoma. J Oral Med 1983;38:87-89.
8. Maqbool M, Ahmad R, Ahmad R. Osteoma of the tongue. Indian Pediatr 1992;29:1429-1431.
9. Kransdorf MJ, Meis JM. Extraskelatal osseous and cartilaginous tumors of the extremities. Radiographics 1993;13:853-884.
10. Turkoz H K, Varnali Y, Comunoglu C. A case of osteolipoma of the head and neck area. Kulak Burun Bogaz Ihtis Derg 2004;13:84-86.
11. Piatelli A, Fioroni M, Iezzi G, Rubini C. Osteolipoma of the tongue. Oral Oncology 2001;37:468-470.
12. Chou L, Hansen LS, Daniels TE. Choristomas of the oral cavity: a review. Oral Surg Oral Med Oral Pathol 1991;72:584-93.