

Intravenous leiomyomatosis of uterus: A case report

Uterusun intravenöz leiomyomatozisi: Olgu sunumu

Esin ATİK¹, Süleyman ALTINTAŞ¹, Bülent AKANSU¹, Şahin ZETEROĞLU², Arif GÜNGÖREN²

Department of Pathology¹, Department of Obstetrics and Gynecology², Faculty of Medicine, Mustafa Kemal University, HATAY

ABSTRACT

Intravenous leiomyomatosis is an uncommon variant of uterine leiomyomas. These tumors originate from smooth muscle cells of veins or lymphatics. Generally, they can't be diagnosed before surgery. Both gross and histopathological findings are important for diagnosis. Growing into the right ventricle through inferior vena cava may be seen in some of the cases. Benign cystic lung metastases have been also reported. In this article, a 42 year-old woman who had 3 children applied to our outpatient clinic of gynecology with pelvic pain and abnormal menstrual bleeding which had started 7 years ago, is presented. In physical examination uterus was palpated as hard, painful, and abnormally large. Total abdominal hysterectomy and unilateral salphingo-oophorectomy was performed with myomatosis uteri prediagnosis. During operation, frozen section specimen was diagnosed as intravenous leiomyomatosis. By presenting this case, we aim both to emphasize the importance of post-diagnosis follow-up of patients, and also evaluate intravenous leiomyomatosis in the light of literature.

Key words: Intravenous leiomyomatosis, leiomyoma, uterus

ÖZET

İntravenöz leiomyomatozisi uterus leiomyomlarının nadir rastlanan bir varyantıdır. Bu tümörler venöz veya lenf damarlarındaki düz kas hücrelerinden kaynaklanmaktadır. Operasyon öncesi tamı genellelikle konulamaz. Tamı postoperatif dönemde makroskopik ve histopatolojik bulgular sonucunda konur. Bu olguların bazılarında vena kava inferior yoluyla sağ kalbe uzanım izlenebilir. Ayrıca benign kistik akciğer metastazlarına rastlandığı da bildirilmiştir. Bu makalede 7 yıldır anormal menstrüel kanama ve pelvik ağrı şikayeti olan, 42 yaşında 3 çocuk sahibi kadın hasta sunulmaktadır. Fizik muayenede uterus sert, ağrılı ve normalden büyüktü. Myomatozis uteri ön tanısı ile hastaya total abdominal histerektomi ve tek taraflı salpingooferektomi uygulandı. Operasyon esnasında yapılan frozen kesite intravenöz leiomyom tanısı verildi. Bu olgu sunumunda intravenöz leiomyomatozisi, literatür bilgileri eşliğinde yeniden ele alınarak, tamı sonrası takibinin önemi vurgulanmaktadır.

Anahtar sözcükler: İntravenöz leiomyomatozisi, leiomyom, uterus

INTRODUCTION

Intravenous leiomyomatosis (IVL) is a rare benign neoplasia which originates from smooth muscle cells of veins or lymphatics. It can be seen in uterine or extrauterine localization. It was first described by Birsh-Hirshfeld in 1896 (1). Generally, there are other leiomyomas in myometrium (1). More than 150 cases have been reported in English literature (2). Despite its

benign character, it can grow into the right ventricle by way of inferior vena cava and sometimes fatal obstruction of pulmonary arteries may accompany these findings (3,4). Also there can be multiple nodular lung metastases.

There are two theories about IVL pathogenesis. The first theory claims that tumor arises from smooth muscle cells in uterine veins. According to the other, it appears as a vascular invasion of a leiomyoma (5).

The patients are generally 23-80 year-old women (6,7). No correlation can be shown

Corresponding Author: Dr. Esin Atik, Mustafa Kemal Üniversitesi Tıp Fakültesi, Patoloji Anabilim Dalı, 31100 Antakya-Hatay

among race, parity and fertility (6,8). Our case was diagnosed by intraoperative frozen section sampling.

CASE REPORT

A 42 year-old woman who had 3 children applied to our outpatient clinic of gynecology with pelvic pain and abnormal menstrual bleeding which had started 7 years ago. In physical examination, uterus was hard, painful and bigger than normal size. There was also bilateral sensitivity at adnexial regions. Ultrasonography (USG) revealed a 22x21 mm subserosal leiomyoma at fundus, a 47x30 mm intracavitary leiomyoma at corpus of uterus and a 20x18 mm cystic lesion at left ovary. Total abdominal hysterectomy unilateral salphingo-oophorectomy (TAH-USO) was performed on the patient with myomatosis uteri pre-diagnosis. During operation, frozen section specimen was diagnosed as IVL by our pathology department (Figure 1). After surgery, a 400 g TAH-USO specimen was sent to our department. A well-circumscribed intramural lesion measuring 5 cm in diameter which protruded outside the uterus under tuba uterine was seen in sections. It was granular in shape and localized on lateral wall of uterus just under tuba uterine (Figure 2). There was also another intramural leiomyoma in fundus. During microscopical examination, it was seen that

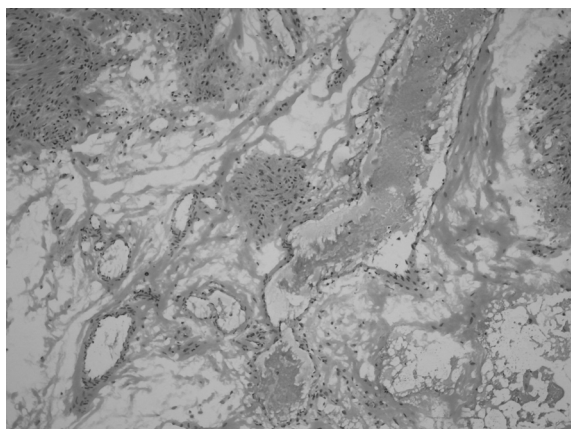


Figure 1. Frozen section of the lesion (HE x100).

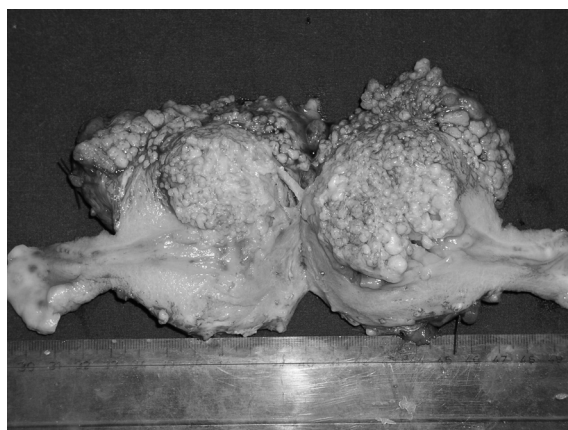


Figure 2. Macroscopic appearance of the well-circumscribed, granular, intramural lesion.

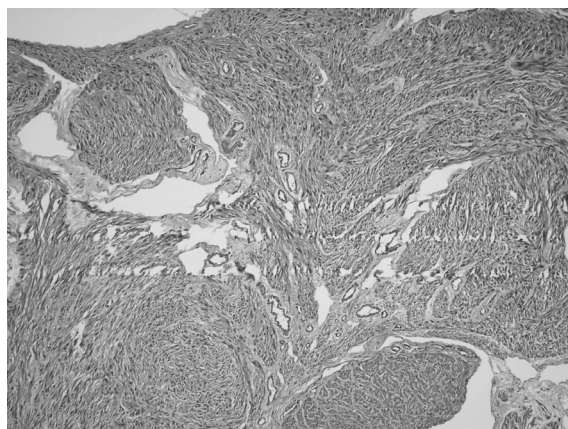


Figure 3. Smooth muscle cells with fusiform nuclei forming groups separated with small and large vascular spaces (HE x100).

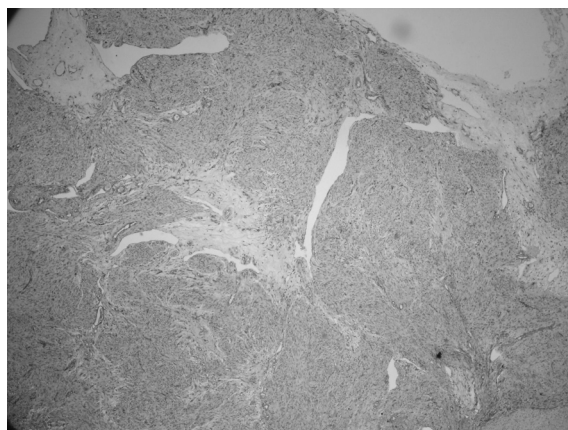


Figure 4. Widespread positivity on vascular walls detected with CD-34 antibody staining (CD-34 x40).

this lesion was composed of smooth muscle cells with fusiform nuclei which formed groups and crossing each other separated with small and large vascular spaces (Figure 3,4).

DISCUSSION

Intravenous leiomyomatosis is generally a benign neoplasm which was described only in females (6,7). Pelvic pain and abnormal uterine bleeding are the most common complaints as seen in our patient. Generally these lesions appear as ordinary leiomyomas during US examinations performed before surgery, and then they are definitely diagnosed as IVL histopathologically.

Although IVL has benign characteristics, it becomes fatal by growing into right ventricle through inferior vena cava (3,4). Asymptomatic nodular lung metastases are also important. These lesions are generally detected accidentally by direct lung graphics taken for other reasons (9).

Total abdominal hysterectomy bilateral salphingo-oophorectomy is usually enough for treatment, but in some cases recurrent pelvic and cardiac tumors may occur after hysterectomy (8). So the patients with IVL should be followed carefully and regularly because of recurrences and risk of tumor emboli. Our patient was diagnosed nearly 6 months ago and still been followed by our Obstetrics and Gynecology Department. Right ventricle failure occurred about 4 months after the operation.

CD-34 immunostaining was performed on sections in our laboratory and widespread positivity on vascular walls were detected (Fig. 4). Immunohistochemical analyses about estrogen and progesterone receptors, vimentin, desmin, smooth muscle actin, CD-10 and h-caldesmon were performed on these lesions by Kir et al. Weak to strong estrogen and progesterone receptor positivity were detected (10). Because of estrogen and progesterone receptors, anti-estrogenic drugs and GnRH agonists can be used as adjuvant therapeutics in tumors that couldn't be

excised totally (11). Mitsuhashi et al. reported good results with GnRH agonists in residual pelvic lesions (12). But some studies indicated that GnRH agonists were ineffective in IVL which had atypical histological features (2).

Hyalinization and hydropic degeneration are the most common features with dilated, thick walled veins as seen in our case (9). Intravascular tumor resembles a typical leiomyoma or it may be a leiomyoma variant cellular, atypical, epithelioid, myxoid characteristics (11). Differential diagnosis should include typical leiomyoma with artifactual retraction from the surrounding myometrium, leiomyoma with vascular invasion, leiomyoma with perinodular hydropic changes and low grade endometrial stromal sarcoma (11).

As a conclusion; cardiac and pulmonary systems should be examined carefully in patients with IVL. Postoperative follow-up is also important for prevention of unwanted problems.

REFERENCES

1. Birch-Hirschfeld FV. Lehrbuch der Pathologischen Anatomie. Vogel, Leipzig, 1896. 5th ed., p.266.
2. Lam PM, Lo KWK, Yu MMY, Lau TK, Cheung TH. Intravenous leiomyomatosis with atypical histologic features: A case report. *Int J Gynecol Cancer* 2003;13:83-87.
3. Grove A, Jørgensen A. Intravascular leiomyomatosis of the uterus. *Path Res Pract* 1996;192:949-956.
4. Fukaya Y, Iida F, Morimoto M. A case report on successful removal of intravenous leiomyomatosis extending in the right ventricle. *Surgery* 1991;110:909-911.
5. Suginami H, Kaura R, Ochi H, Matsuura S. Intravenous leiomyomatosis with cardiac extension :successful surgical management and histopathological study. *Obstet Gynecol* 1990;76:527-529.
6. Clement PB, Young RH, Scully RE. Diffuse perinodular and other patterns of hydropic degeneration within and adjacent to uterine leiomyomas. Problems in differential diagnosis. *Am J Surg Pathol* 1992;16:26-32.
7. Mulvany NJ, Slavin JL, Ostor AG, Fortune DW. Intravenous leiomyomatosis of the uterus: a clinicopathologic study of 22 cases. *Int J Gynecol Pathol* 1994;13:1-9.
8. Zaloudek C, Hendrickson MR. Mesenchymal tumors of the uterus. In Kurman RJ (ed). *Blaustein's Pathology of the Female Genital Tract*, 5th ed., Springer -Verlag, New York, 2002. pp.575-577.
9. Matsumoto K, Yamamoto T, Hisayoshi T, Asono G. Intravenous leiomyomatosis of the uterus with multiple pulmonary metastases associated with large bullae -

- like cyst formation. *Pathol Int* 2001;51:396-401.
10. Kir G, Kir M, Gurbuz A, Karateke A, Aker F. Estrogen and progesterone expression of vessel walls with intravascular leiomyomatosis; discussion of histogenesis. *Eur J Gynaecol Oncol* 2004;25(2):236 (abstr).
 11. Ala Andrade L, Torresan RZ, Sales JFS, Jr. Vicentini R, A De Souza G. Intravenous leiomyomatosis of the uterus. *Pathology Oncology Research* 1998;1:44-47.
 12. Mitsuhashi A, Nagai Y, Sugita M, Nakajima N, Sekiya S. GnRH agonist for intravenous leiomyomatosis with cardiac extension. *J Reprod Med* 1999;44:883-886.