



# Oral Focal Epithelial Hyperplasia: Report of Three Cases

## Oral Fokal Epitel Hiperplazisi: Üç Olgu Sunumu

Parichehr GHALAYANI<sup>1</sup>, Payam TAVAKOLI<sup>2</sup>, Mehdi EFTEKHARI<sup>3</sup>, Mohammad Akhondzadeh HAGHIGHI<sup>1</sup>

<sup>1</sup>Department of Oral Medicine and Torabinejad Dental Research Center, Isfahan University of Medical Sciences, School of Dentistry, ISFAHAN, IRAN

<sup>2</sup>Department of Oral & Maxillofacial Pathology, Kermanshah University of Medical Sciences, School of Dentistry, KERMANSHAH, IRAN

<sup>3</sup>Department of General Pathology, Ahwaz University of Medical Sciences, School of Medicine, AHWAZ, IRAN

### ABSTRACT

Focal epithelial hyperplasia or Heck's disease is an infrequent asymptomatic condition caused by human papillomavirus types 13 or 32 affecting the mucous membrane of the mouth and is commonly seen in young individuals. Firstly, it was described in Indians and Eskimos, but it exists in various populations. We present three cases of Heck's disease in an Afghan immigrant family group living in Iran that seem to have familial predominance. The disease was identified as oral focal epithelial hyperplasia on the basis of histopathologic and clinical findings. The lesions were reduced significantly after 4 months of good oral hygiene. Dentists should be familiar with the clinical manifestations of these types of lesions that affect the oral cavity. In fact, histopathologic assessment and clinical observation are necessary to establish the diagnosis.

**Key Words:** Focal epithelial hyperplasia, Heck disease, Buccal mucosa

### ÖZ

Fokal epitelyal hiperplazi veya Heck hastalığı, human papillomavirus tip 13 veya 32 ilişkili oral mukozal membranları etkileyen, sıklıkla genç erişkinlerde görülen asemptomatik nadir bir hastalıktır. İlk olarak Amerikan yerlilerinde ve Eskimolarda tanımlanmış olmasına karşın diğer etnik guruplarda da görülmektedir. İran'da yaşayan Afganistan göçmeni ailede, aynı aile bireyleri olmaları nedeniyle ailesel predispozisyon ile ilişkili olduğu düşünülen 3 olgu tanımlamaktayız. Olgular klinik ve histopatolojik özellikleri nedeniyle fokal epitelyal hiperplazi tanısı almışlardır. Lezyonlar oral hijenin iyileştirilmesini takiben 4 ay sonra belirgin olarak gerilemiştir. Hastalığın tanınabilmesi için diş hekimleri oral kaviteyi etkileyen bu tip lezyonların klinik bulgularının farkında olmalıdırlar. Tanı histopatolojik inceleme ve klinik değerlendirme ile konur.

**Anahtar Sözcükler:** Fokal epitelyal hiperplazi, Heck hastalığı, Yanak mukozası

### INTRODUCTION

One of the most contagious oral lesions is focal epithelial hyperplasia or Heck's disease, induced by human papillomavirus (HPV). The earliest description of the condition was in 1965 by Archard et al in Native Americans and Inuits (1). The disease is more common among younger age groups and occasionally there is some tendency to occur in families. This familial tendency may be related to either genetic susceptibility or HPV transmission between family members. (2).

The most common sites of involvement include the labial, buccal, and lingual mucosa, but gingival and palatal lesions also have been reported. This disease normally manifests as multiple soft, flattened or rounded papules, which are usually clustered and the color of normal mucosa, although they may be scattered, pale, or rarely white. Notably, the lesions have a tendency to disappear on their own (1,2).

There is an etiological link between papillomavirus and this lesion. Moreover, living conditions such as malnutrition, poor hygiene and also genetic factors have been related to this disease (3).

This paper reports 3 cases of focal epithelial hyperplasia that have familial predominance in an Afghan family group. Besides, the diagnosis is based on histopathological features.

### CASE REPORTS

Three patients from an Afghan community were referred to the department of oral pathology, school of dentistry, Isfahan University of Medical Sciences. Two of the cases were siblings and one of whom was their uncle.

Case 1 was a 30 years old man suffering from painless small elevations on oral mucosa in the last 6 months. He had no history of previous systemic disease, and he had not taken any medications. His oral examination revealed normal-colored to white papules, mainly located on the buccal

(*Türk Patoloji Derg* 2015, 31:60-63)

Received : 22.10.2011 Accepted : 14.05.2012

**Correspondence:** Payam TAVAKOLI

Kermanshah University of Medical Sciences, School of Dentistry,  
Department of Oral & Maxillofacial Pathology, KERMANSHAH, IRAN  
E-mail: payam1111@yahoo.com Phone: +98 913 117 45 22

mucosa, mucosa of the lower lip and tongue. The lesions were not ulcerated nor inflamed (Figure 1A).

Case 2 was the nephew of case 1. She was a 12-year-old girl presented with about 5 months history of asymptomatic growths on her mouth. The patient did not report any systemic disease. Her oral examination revealed several papules measuring 0.2 to 1.0 cm extended over the buccal and labial mucosa. Moreover, the lesions on the right cheek occasionally had interference with mastication that resembled a string of beads (Figure 1B).

Case 3 was the brother of case 2. He was a 5-year-old boy without any systemic condition who complained of multiple asymptomatic lesions in his mouth for about 5 months. Intraoral examination showed multiple elevated pinkish papules on the buccal, upper and lower lip mucosa. All three patients described here were presented with poor dental hygiene.

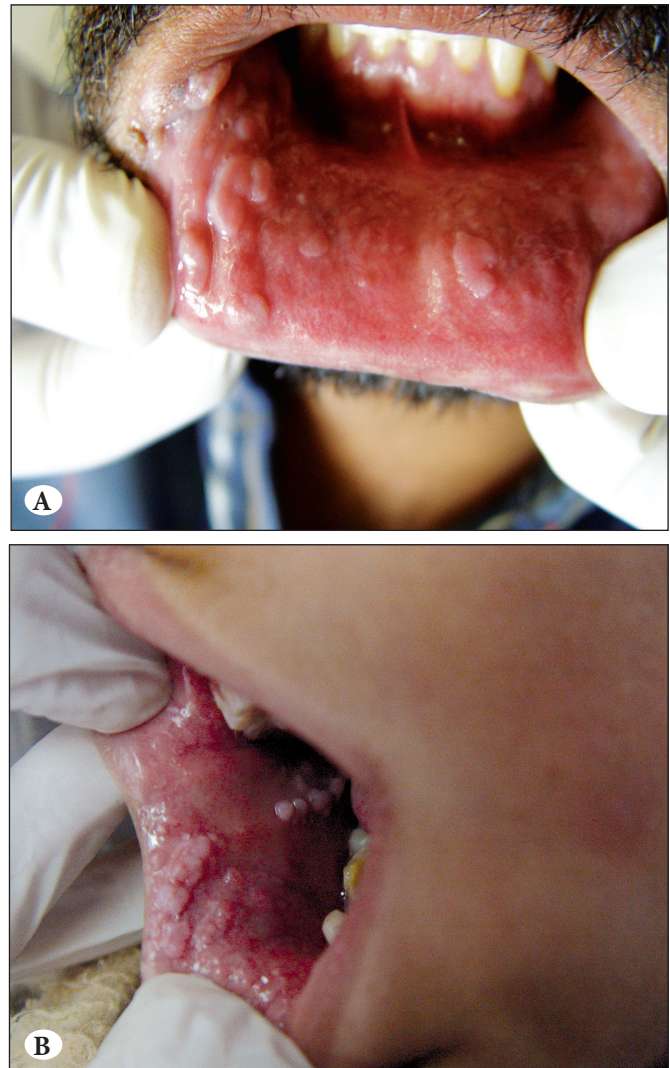
The clinical diagnosis of focal epithelial hyperplasia was straightforward; however, in order to confirm the diagnosis a biopsy was performed on the largest lesions of labial and buccal mucosa after applying local anesthesia and the specimens were submitted for histopathologic evaluation. The histopathological assessment showed a squamous epithelium displaying regional parakeratosis, acanthosis (Figure 2A), basal cell hyperplasia, vacuolization of numerous epithelial cells (koilocytosis) (Figure 2B), Occasional binucleation and nuclear irregularity. There was no epithelial dysplasia. Also, collapsed nucleus that resembles a mitotic figure (mitosoid cell) was obvious (Figure 2C).

We advised the patients to have better oral and general hygiene. The lesions disappeared remarkably after 4 months illustrated in figure 3A and 3B.

## DISCUSSION

Focal epithelial hyperplasia is an HPV induced epithelial proliferation. This disease appears to be uncommon. According to literature, a few cases of Heck's disease have been reported in Iran (4,5). This might be due to lack of the reports. We show three cases of focal epithelial hyperplasia in Afghan patients. Children are affected more frequently with a female-to-male predilection of approximately 4-5:1 (6,7). The multiple papillary lesions like Heck's disease are especially common among HIV positive individuals (8).

The human papillomavirus is associated with proliferations of squamous mucosa in this process. Type 13 and 32 has been detected with polymerase chain reaction (9,10). It should be mentioned that HPV 6, 11 and 18 have been

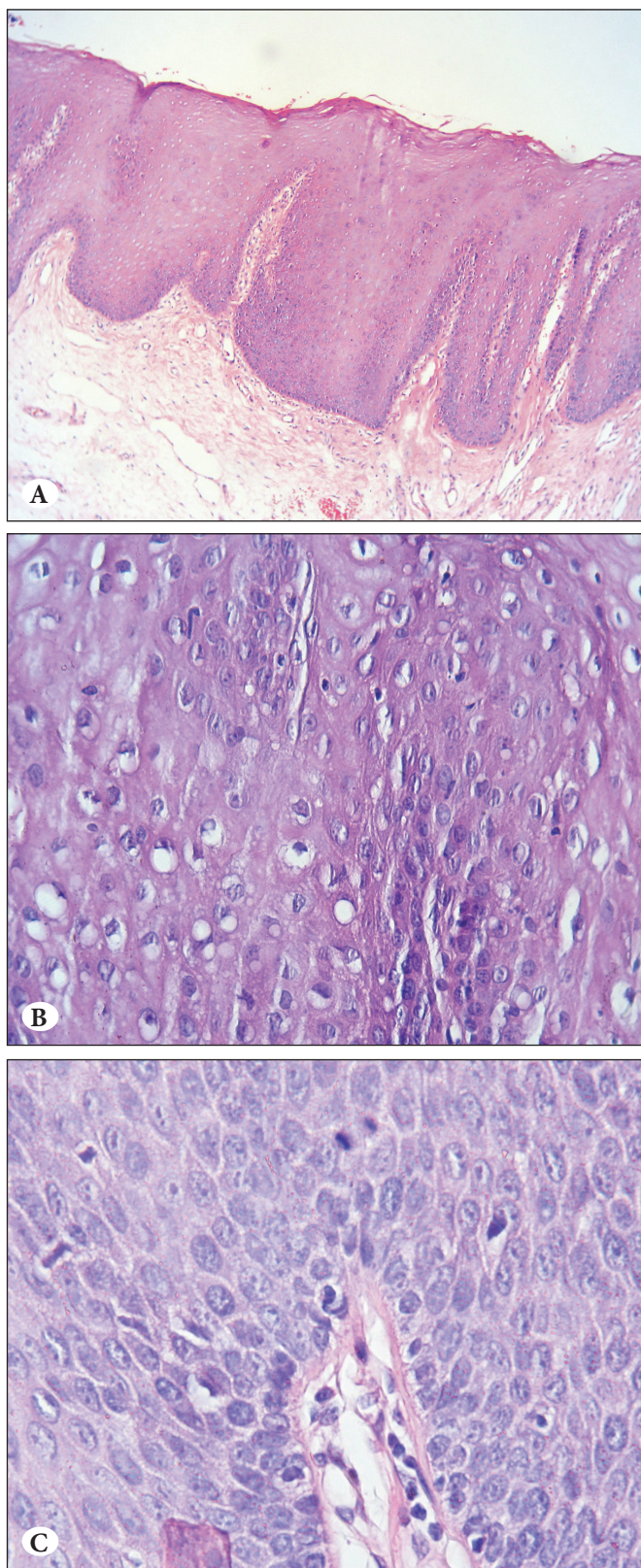


**Figure 1A, B:** Patient with multiple lesions in labial and buccal mucosa.

found as well (11). The oral cavity can be the site of a variety of HPV-related lesions, some of which are microscopically and behaviorally benign. These include focal epithelial hyperplasia (Heck's disease), verruca vulgaris, condyloma acuminatum and squamous papilloma (12). Human-to-human transmission has been assumed to be the most important mode of contact. However, the virus could be transmitted from mother to child (12). This helps to explain why Heck disease occurs in child group and its familial tendency. Notably, poor nutrition, hygiene and overall health may be related to disease (5). These conditions comply with our cases.

Histological examination illustrated acanthosis of the oral epithelium. The rete ridges were widened, often confluent, and sometimes club shaped. Some superficial keratinocytes

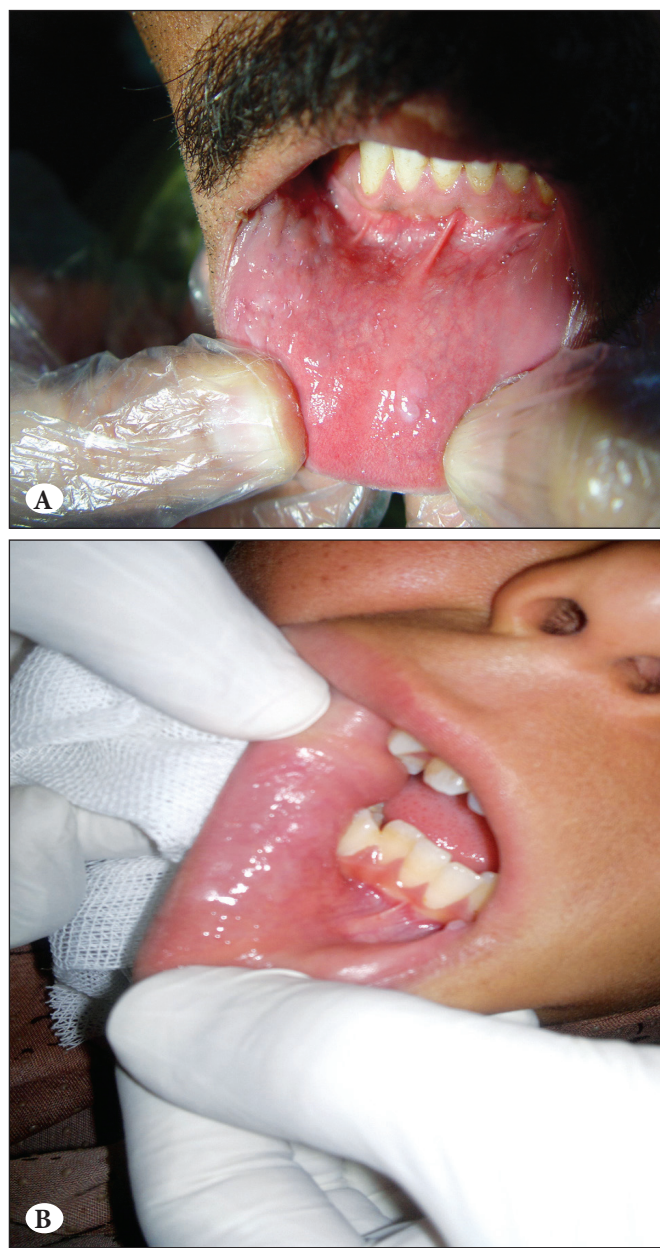




**Figure 2:** Histopathology of Heck disease. A) Acanthosis of the epithelium with broad and elongated rete ridges (H&E; ×100). B) Isolated perinuclear cellular vacuolization (H&E; ×400). C) Mitosoid cell (H&E; ×1000).

showed a koilocytic change similar to that seen in other HPV infections. Others occasionally demonstrate an altered nucleus that resembles a mitotic figure (mitosoid cell) (13).

Spontaneous regression of multifocal epithelial hyperplasia has been reported after months or years by enhancing oral and general hygiene (as we observed in all 3 patients), nevertheless, application of local cryotherapy has been used as well (14). Also, application of vitamin A and sulfamides has been recommended by Archard and co-workers (1).



**Figure 3A,B:** Remission of the lesions after 4 months of promoting good oral hygiene.

## REFERENCES

1. Archard HO, Heck JW, Stanley HR. Focal epithelial hyperplasia: An unusual oral mucosal lesion found in Indian children. *Oral Surg Oral Med Oral Pathol.* 1965;20:201-12.
2. Terezhalmay GT, Riley CK, Moore WS. Focal epithelial hyperplasia (Heck's disease). *Quintessence Int.* 2001;32:664-5.
3. Carlos R, Sedano HO. Multifocal papilloma virus epithelial hyperplasia. *Oral Surg Oral Med Oral Pathol.* 1994;77:631-5.
4. Moussavi S. Focal epithelial hyperplasia: Report of two cases and review of literature. *J Am Dent Assoc.* 1986;113:900-2.
5. Hashemipour MA, Shoryabi A, Adhami S, Mehrabizadeh Honarmand H. Extensive focal epithelial hyperplasia. *Arch Iran Med.* 2010;13:48-52.
6. Bennett LK, Hinshaw M. Heck's disease: Diagnosis and susceptibility. *Pediatr Dermatol.* 2009;26:87-9.
7. Yasar S, Mansur AT, Serdar ZA, Goktay F, Aslan C. Treatment of focal epithelial hyperplasia with topical imiquimod: Report of three cases. *Pediatr Dermatol.* 2009;26:465-8.
8. Viraben R, Aquilina C, Brousset P, Bazex J. Focal epithelial hyperplasia (Heck disease) associated with AIDS. *Dermatology.* 1996;193:261-2.
9. Syrjanen SM, Syrjanen KJ, Happonen RP, Lamberg MA. In situ DNA hybridization analysis of human papillomavirus (HPV) sequences in benign oral mucosal lesions. *Arch Dermatol Res.* 1987;279:543-9.
10. Premoli-de-Percoco G, Christensen R. Human papillomavirus in oral verrucal-papillary lesions. A comparative histological, clinical and immunohistochemical study. *Pathologica.* 1992;84:383-92.
11. Pfister H, Hettich I, Runne U, Gissmann L, Chalf GN. Characterization of human papillomavirus type 13 from focal epithelial hyperplasia Heck lesions. *J Virol.* 1983;47:363-6.
12. Kumaraswamy KL, Vidhya M. Human papilloma virus and oral infections: An update. *J Cancer Res Ther.* 2011;7:120-7.
13. Ledesma-Montes C, Garces-Ortiz M, Hernandez-Guerrero JC. Clinicopathological and immunocytochemical study of multifocal epithelial hyperplasia. *J Oral Maxillofac Surg.* 2007;65:2211-7.
14. Ledesma-Montes C, Vega-Memije E, Garces-Ortiz M, Cardiel-Nieves M, Juarez-Luna C. Multifocal epithelial hyperplasia. Report of nine cases. *Med Oral Patol Oral Cir Bucal.* 2005;10:394-401.