



Vernix Caseosa Peritonitis: Report of Two Cases

Verniks Kazeoza Peritoniti: İki Olgu Sunumu

José-Fernando VAL-BERNAL, Marta MAYORGA, Pilar GARCÍA-ARRANZ, Waleska SALCEDO, Alicia LEÓN, Fidel A. FERNÁNDEZ

Department of Anatomical Pathology, Marqués de Valdecilla University Hospital, Medical Faculty, University of Cantabria and Idival, SANTANDER, SPAIN

ABSTRACT

Vernix caseosa peritonitis is a rare complication caused by inflammatory response to amniotic fluid spilled into the maternal peritoneal cavity. Most cases occur after cesarean section. We discuss herein two patients, aged 33 and 29 years, who presented with vernix caseosa peritonitis seven to nine days after a cesarean delivery. Laparotomy was performed and it revealed neither uterine rupture nor other surgical emergencies, but cheesy exudates on the serosal surface of all viscera. Appendicectomy was performed. Histopathologic study revealed acute fibrinous serositis and a mixed cellular infiltrate, rich in neutrophils, around fetal desquamated anucleate squamous cells. Patients' recovery was complete. Clinical diagnosis of vernix caseosa peritonitis should be suspected in patients presenting post-cesarean section with an acute abdomen. Distinctive histopathologic findings allow making the correct diagnosis. Vigilant monitoring after diagnosis is essential as delayed morbidities may appear.

Key Words: Cesarean section, Peritonitis, Vernix caseosa

ÖZ

Verniks kazeoza peritoniti, amniyotik sıvının maternal peritoneal kavite içerisine yayılması sonucu oluşan, inflamatuvar yanıtın oluşturduğu ender bir komplikasyondur. Olguların büyük kısmı sezaryen sonrası ortaya çıkar. Biz burada sezaryen sonrası, yedi ve dokuzuncu günlerde verniks kazeoza peritonitis ile kendini gösteren 33 ve 29 yaşlarındaki iki hastayı tartıştık. Yapılan laparatomide uterus rüptürü veya diğer herhangi bir cerrahi acil durum ile karşılaşmadı ancak tüm iç organların serozal yüzeylerini kaplayan peynirimsi eksüda saptandı. Apendektomi yapıldı. Histopatolojik değerlendirmede akut fibrinöz serozit ve nükleus içermeyen fetal deskuame skuamöz epitel hücreleri çevresinde nötrofillerden zengin mikst hücrel infiltrasyon görüldü. Sezaryen sonrası akut karın bulguları gösteren hastalarda klinik olarak verniks kazeoza peritonitinden şüphelenilmelidir. Ayırt edici histopatolojik bulguları doğru tanı konulmasını sağlar. Geç morbiditeler ortaya çıkabileceğinden tanı sonrası dikkatli izlem gereklidir.

Anahtar Sözcükler: Sezaryen, Peritonit, Verniks kazeoza

INTRODUCTION

Vernix caseosa peritonitis (VCP) is a rare, poorly recognized complication caused by inflammatory response to amniotic fluid spilled into the maternal peritoneal cavity. This entity has distinctive histopathologic findings (1). Only 28 cases of this process have been reported in the literature to date (2).

We present herein two cases observed in women after a recent cesarean section. Our aim is to increase awareness among obstetricians, surgeons and pathologists of the clinical presentation, intra-operative findings and microscopic characteristics of the VCP.

CASE REPORTS

Case 1

A 33-year-old woman, gravida 3, para 1, was admitted at 43 weeks gestation in active labor with regular contractions. Membranes were not ruptured. Past medical history was significant for gestational diabetes and hypothyroidism

treated with insulin and levothyroxine sodium, cesarean delivery at term in the first pregnancy, and ectopic pregnancy with left salpingectomy in the second pregnancy.

A low transverse cesarean section was performed and a live, normal baby was delivered. The patient's postoperative recovery was unremarkable and she was discharged two days later.

Nine days postpartum, the patient was readmitted suffering from generalized abdominal pain. Pyrexia was not observed. Positive Blumberg's sign and marked leukocytosis were detected and the patient was diagnosed with acute abdomen probable appendicitis. At laparotomy, cheesy, fibrinous debris was found throughout the peritoneal cavity. Appendicectomy and extensive peritoneal lavage was performed. Postoperatively, she was treated with gentamicin, meropenem and enoxaparin sodium. Recovery was uneventful and she was discharged on the 14th postoperative day.

(*Türk Patoloji Derg* 2015, 31:51-55)

Received : 24.05.2014 Accepted : 25.06.2014

Correspondence: José-Fernando VAL-BERNAL

University of Cantabria, Pathology Unit, SANTANDER, SPAIN

E-mail: apavbj@humv.es Phone: +34942 202520/ext. 73232

Case 2

A 29-year-old woman, gravida 1, para 0, was delivered by an uncomplicated lower segment cesarean section at 41 weeks gestation for breech presentation after an unremarkable antenatal control. She developed generalized abdominal pain and pyrexia (39.5°C) seven days later. Physical examination revealed positive diffuse abdominal tenderness and Blumberg's sign. A neutrophilic leukocytosis was present. At laparotomy for suspected appendicitis, numerous areas of cheese-like fibrinous exudates were observed on the serosal surface of the viscera. An appendicectomy and extensive peritoneal lavage was performed.

Postoperatively, she was treated with enoxaparin sodium and acetaminophen. She recovered well and was discharged on the 4th postoperative day.

Pathology Findings

Microscopic examination of both appendices demonstrated multiple fibrinocellular exudates on the serosa (Figure 1).

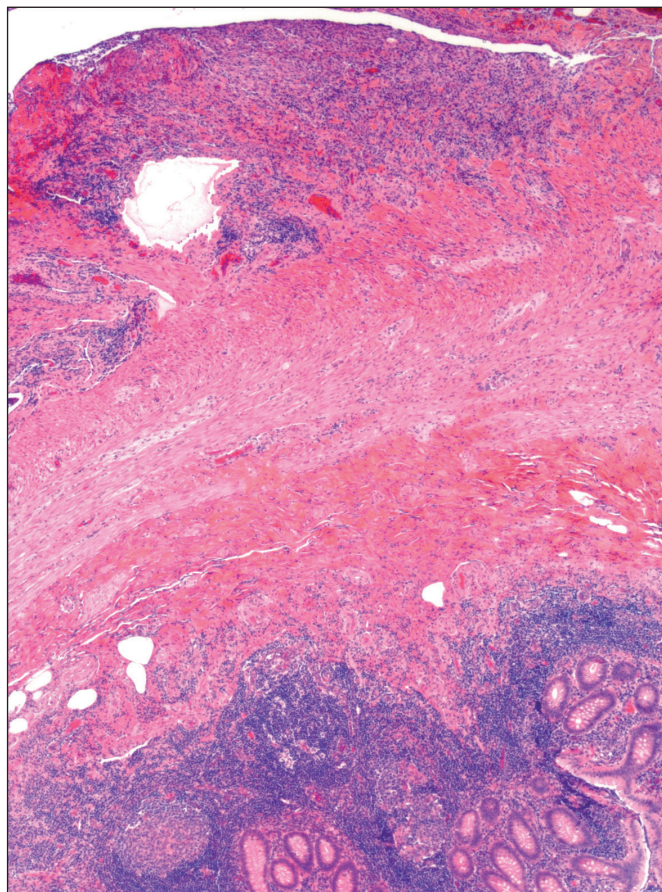


Figure 1: Panoramic view of the appendix showing acute fibrinous inflammation on the serosa (H&E; x25).

The inflammatory cells included an admixture of neutrophils, eosinophils, lymphocytes and macrophages aggregated about anucleate squamous cells having wrinkled borders (Figure 2). Occasionally, a foreign body giant cell reaction was present (Figure 3). Besides, a lanugo hair shaft surrounded by inflammatory cells was identified in case 2 (Figure 4). There was intensive hyperemia and hemorrhagic foci. The anucleate squamous cells showed strong positivity for AE1/AE3 cytokeratin (Figure 5). Proliferating (reactive) submesothelial spindle cells also displayed strong positivity for AE1/AE3 cytokeratin.

DISCUSSION

Vernix caseosa is the cheese-like substance covering the skin of the newborn. This material in the amniotic fluid consists of an admixture of (i) fetal desquamated, anucleate, squamous, epithelial cells, (ii) lanugo hair shafts, and (iii) sebaceous glandular secretion. Biochemical studies have revealed presence of lipids (62.5%), proteins (36%), and carbohydrates (1.5%) (3).

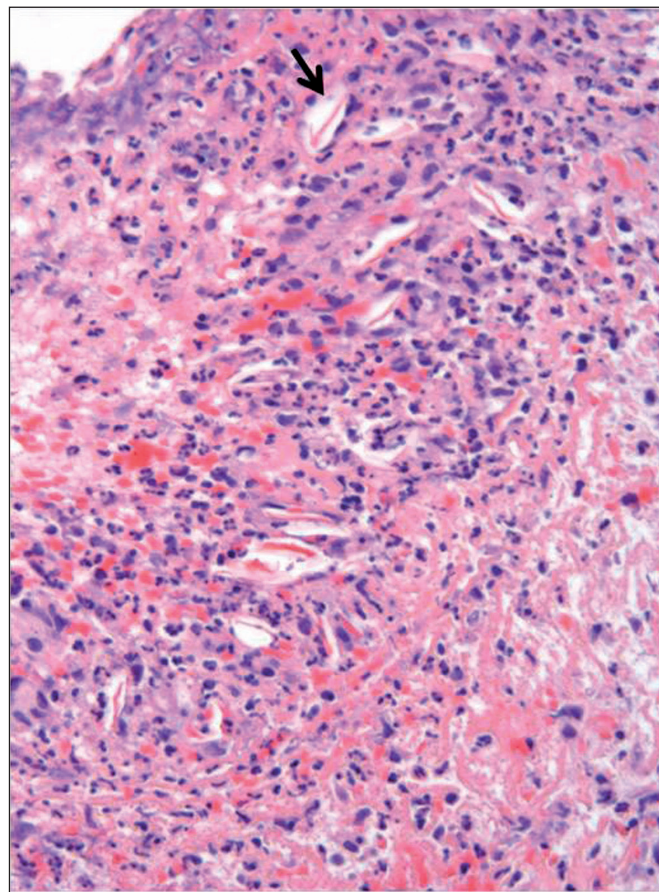


Figure 2: Scattered anucleate squamous cells are surrounded by a mixed inflammatory infiltrate. The arrow indicates an anucleate squamous cell (H&E; x200).

Spillage of vernix caseosa into the peritoneal cavity is believed to incite an inflammatory reaction causing symptoms resembling an acute abdomen. The leakage of amniotic fluid can occur as a result of antenatal or intrapartum tubal reflux (2,4), uterine perforation (5), or during cesarean section (1). Most cases reported were diagnosed in the postpartum period after uneventful cesarean section.

The spillage of amniotic fluid into peritoneal cavity at cesarean section is almost inevitable and usually insignificant. However, in some cases it can be the trigger for a peritoneal reaction. The exact mechanism leading to the development of peritonitis in these few cases is unknown (6). The onset of VCP occurring after uncomplicated caesarean sections has been attributed to incomplete peritoneal lavage of spilled amniotic fluid (4). In spite of that, surgeons have caution in performing excessive peritoneal lavage, intestinal manipulation and the use of pads that could favor the formation of postsurgical adhesions. Keratinized squamous cells have demonstrated

the capacity to induce an active inflammatory response by mechanical (7) or chemical irritation (8). Thus, a peritonitis picture can be observed following rupture of an ovarian mature cystic teratoma (dermoid cyst). The keratin and sebum present in the tumor lumen may provoke an extensive and prominent foreign body reaction that mimics peritoneal carcinomatosis (9). Some authors consider that a higher concentration of vernix caseosa in amniotic fluid, observed in difficult labors with partial loss of amniotic fluid, or in oligohydramnios cases, may have pathogenic significance (4). Therefore, the concentration of vernix caseosa in the amniotic fluid could operate as a pathogenic factor. Nevertheless vernix caseosa is not present in all newborns. Monteagudo et al. (10) observed this material in 43% of newborns infants.

On the other hand, a hypersensitivity reaction may take place from sensitization occurring from previous pregnancy and delivery. However, some cases of VCP develop in primiparous women suggesting that hypersensitivity reaction is less likely. The main symptoms of VCP are generalized severe abdominal pain, pyrexia, peritonism, and neutrophilic leukocytosis within 3 to 35 days following cesarean section (11,12). The imaging techniques show non-specific changes or are normal. Diagnostic laparoscopy

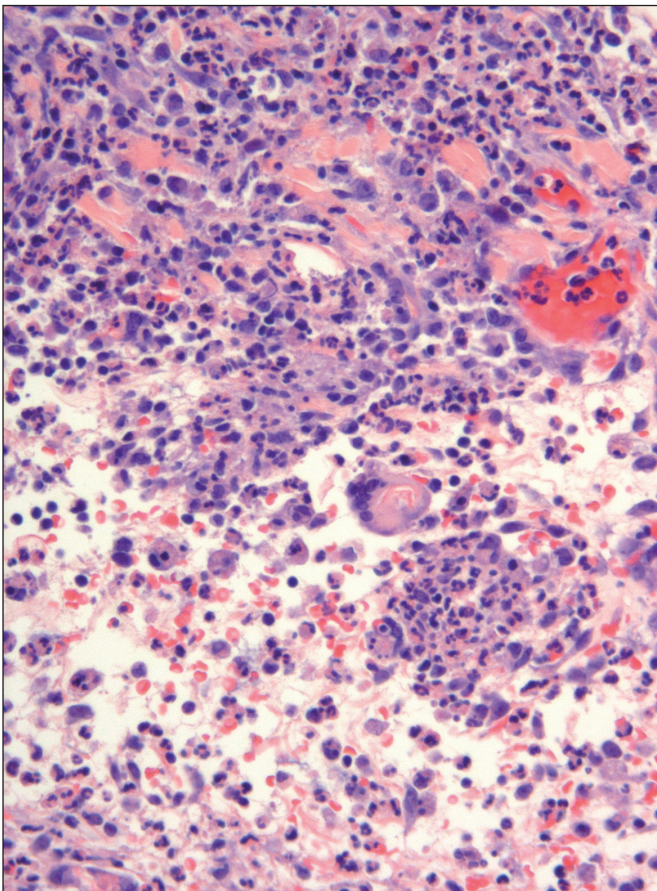


Figure 3: Mixed inflammatory infiltrate with presence of a multinucleate giant cell. This cell shows rests of squamous cells engulfed in its cytoplasm (H&E; x200).

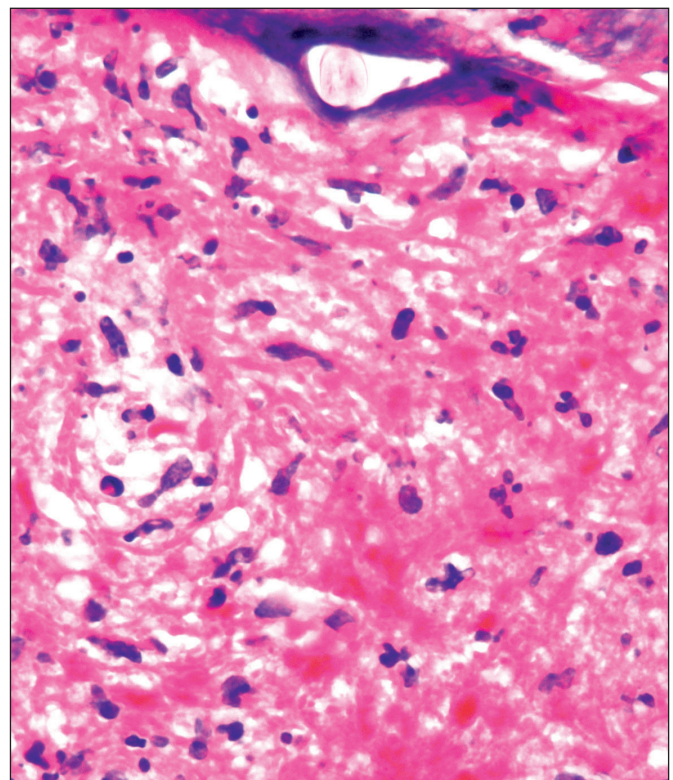


Figure 4: Lanugo hair shaft amidst inflammatory cells (H&E; x400).

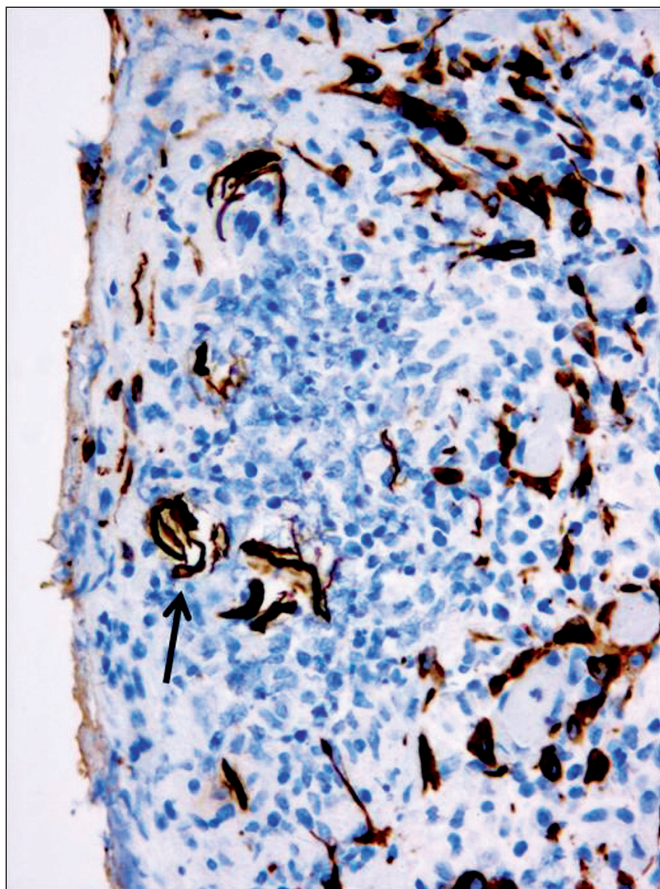


Figure 5: Anucleate squamous cells and proliferating submesothelial cells show strong positivity for AE1/AE3 cytokeratin. The arrow points to an aggregate of anucleate squamous cells (Cytokeratin; x200).

or laparotomy to exclude other more frequent process (appendicitis, ruptured viscus, bowel or ureter injury) shows characteristic white and yellow cheese-like plaques deposited on visceral and parietal peritoneal surfaces throughout the abdominal cavity. Appendicectomy, peritoneal, or omental biopsies are diagnostic showing an acute, chronic, or mixed cellular inflammatory infiltrate around anucleated, polygonal, epithelial squamous cells (sometimes accompanied by lanugo hair shafts) depending on the time from exposure to diagnosis. The squamous cells are arranged single or in groups and the cheesy exudate is fibrinous in nature. Thus, pathologists are in a unique position to make the correct diagnosis in intra-operative or deferred consultation.

Awareness of the characteristics of VCP helps to avoid extensive excisional procedures that have been performed in the past on suspicion of other processes, such as total hysterectomy, salpingo-oophorectomy, cholecystectomy or partial colectomy, with subsequent normality in the histopathological study of these organs (1,13).

Our case 1 received antibiotic treatment and our case 2 did not. That treatment was a preference of the obstetrician. Some authors have advocated postoperative antibiotic therapy (5-7,11-13), and even adjuvant steroid therapy in cases with resistant symptoms when infection has been excluded (6). However, these treatments remain empirical and controversial since none of them are really evidence-based (2). Furthermore, aggressive treatment with broad-spectrum antibiotics may trigger an acute *Clostridium perfringens* infection (7).

Surely the number of cases of pauci-symptomatic VCP is much higher than assumed. Sometimes patients report discomfort, mild abdominal pain or low grade fever as the only symptom. These symptoms are present in numerous postpartum processes including subclinical forms of VCP (1).

Conservative treatment usually leads to a complete recovery. Nevertheless, occasionally the process may have a protracted course with co-morbidities, including adhesions, bowel obstruction and secondary infection, requiring surgical and medical intervention (14). Therefore, the postoperative course of VCP should be closely monitored.

As for potential preventive strategy, obstetricians should be aware that an increasing caesarean section rate with a consequent increase in caesarean complications can be responsible for the appearance of more cases of VCP (14). Thus, the indications for cesarean delivery should be strictly applied.

In conclusion, VCP is a rare complication of cesarean section caused by spillage of amniotic fluid into the peritoneal cavity. The diagnosis should be suspected in any patient presenting with postcesarean delivery acute abdomen. Suggestive cheesy exudates may be observed in laparoscopy or laparotomy. Diagnosis requires close involvement with the pathologist. VCP is usually a self-limiting condition that usually resolves with conservative management alone. Vigilant monitoring after diagnosis is required as delayed morbidities may arise.

REFERENCES

1. George E, Leyser S, Zimmer HL, Simonowitz DA, Agress RL, Nordin DD. Vernix caseosa peritonitis. An infrequent complication of cesarean section with distinctive histopathologic features. *Am J Clin Pathol.* 1995;103:681-4.
2. Sadath SA, Abo Diba FI, Nayak S, Shamali IA, Diejomaoh MF. Vernix caseosa peritonitis after vaginal delivery. *Clin Med Insights Case Rep.* 2013;6:147-52.
3. Baker SM, Balo NN, Abdel Aziz FT. Is vernix caseosa a protective material to the newborn? A biochemical approach. *Indian J Pediatr.* 1995;62:237-9.

4. Davis JR, Miller HS, Feng JD. Vernix caseosa peritonitis: Report of two cases with antenatal onset. *Am J Clin Pathol.* 1998;109:320-3.
5. Schwartz IS, Bello GV, Feigin G, Sherman DH. Maternal vernix caseosa peritonitis following premature rupture of fetal membranes. *JAMA.* 1985;254:948-50.
6. Mahmoud A, Silapaswan S, Lin K, Penney D. Vernix caseosa: An unusual cause of post-cesarean section peritonitis. *Am Surg.* 1997;63:382-5.
7. Tawfik O, Prather J, Bhatia P, Woodroof J, Gunter J, Webb P. Vernix caseosa peritonitis as a rare complication of cesarean section. A case report. *J Reprod Med.* 1998;43:547-50.
8. Clement D, Barranger E, Benchimol Y, Uzan S. Chemical peritonitis: A rare complication of an iatrogenic ovarian dermoid cyst rupture. *Surg Endosc.* 2003;17:658.
9. Maiti S, Fatima Z, Anjum ZK, Hopkins RE. Ruptured ovarian cystic teratoma in pregnancy with diffuse peritoneal reaction mimicking advanced ovarian malignancy: A case report. *J Med Case Rep.* 2008;2:203.
10. Monteagudo B, Labandeira J, León-Muñoz E, Romarís R, Ramírez-Santos A, González-Vilas D, Fernández-Prieto R, Toribio J. Influence of neonatal and maternal factors on the prevalence of vernix caseosa. *Actas Dermosifiliogr.* 2011;102:726-9.
11. Selo-Ojeme D. Vernix caseosa peritonitis. *J Obstet Gynecol.* 2007;27:660-3.
12. Chambers AC, Patil AV, Alves R, Hopkins JC, Armstrong J, Lawrence RN. Delayed presentation of vernix caseosa peritonitis. *Ann R Coll Surg Engl.* 2012;94:548-51.
13. Cummings B, Scarth HM, Tran HT, Walley VM. Vernix caseosa peritonitis presenting post partum as acute cholecystitis. *Can J Surg.* 2001;44:298-300.
14. Stuart OA, Morris AR, Baber RJ. Vernix caseosa peritonitis - no longer rare or innocent: A case series. *J Med Case Rep.* 2009;3:60.