Case Report doi: 10.5146/tjpath.2026.15124

Pre-Mortem Histopathologic Evidence of Endothelial Injury and Thrombotic Microangiopathy in an Infant With SARS-CoV-2–Associated Multisystem Inflammatory Syndrome (MIS-C)

Meral UNER[1], Fariba AMINI[1], Sefika KARABULUT[2,3], Diclehan ORHAN[4]

[1]Department of Pathology, Hacettepe University Faculty of Medicine, ANKARA, TÜRKIYE
[2]Bionix Laboratory, ANKARA, TÜRKIYE
[3]Department of Medical Microbiology and Virology, Gülhane Institute of Health Sciences, ANKARA, TÜRKIYE
[4]Pediatric and Perinatal Pathology Unit, Hacettepe University Faculty of Medicine, ANKARA, TÜRKIYE

Turk Patoloji Derg 2026, 42:I-VII **Received:** 21.01.2026 **Accepted:** 05.05.2026 **Published Online:** 22.06.2026

ABSTRACT

Multisystem inflammatory syndrome in children (MIS-C) represents a severe postinfectious hyperinflammatory condition following SARS-CoV-2 infection. Despite extensive clinical characterization, histopathologic data—especially from pre-mortem pediatric biopsies—remain scarce.

We report a 9-month-old male infant with confirmed SARS-CoV-2 infection and rapid multiorgan failure. Pre-mortem incisional biopsies from the myocardium, lung, and pleura revealed degenerative myocyte changes, endothelial swelling, and fibrin-platelet microthrombi consistent with thrombotic microangiopathy. Immunohistochemistry demonstrated mild $CD3^+$ T-cell–predominant infiltrates and focal SARS-CoV-2 antigen positivity confined to alveolar and bronchiolar epithelium, while myocardial and pleural tissues were negative.

These findings highlight early morphologic correlates of immune-mediated vascular injury in MIS-C, characterized by endothelial dysfunction, microvascular inflammation, and T-cell-driven immunopathology in the absence of direct viral cytopathy. This case provides rare pre-mortem evidence of immune-thrombotic endotheliopathy in an infant, bridging clinical and histologic manifestations of pediatric SARS-CoV-2–associated hyperinflammatory disease.

Keywords: Covid19, SARS-CoV2, MIS-C, Thrombotic microangiopathy, Infant

INTRODUCTION

Multisystem Inflammatory Syndrome in Children (MIS-C) is a delayed post-infectious hyperinflammatory condition that typically develops two to six weeks after exposure to or infection with severe acute respiratory syndrome coronavirus 2 (SARS-CoV-2), characterized by persistent fever, elevated inflammatory markers, and dysfunction of multiple organ systems—most frequently the cardiovascular, gastrointestinal, mucocutaneous, and hematologic systems (1,2). Although acute COVID-19 in children is generally mild, MIS-C represents a distinct post-viral immune dysregulation syndrome with clinical overlap to Kawasaki disease and toxic shock syndrome but occurring in older children and showing more pronounced myocardial and vascular involvement (3,4). Epidemiologic data indicate that MIS-C is rare but clinically significant, with reported mortality of 1–2% and intensive care requirements in a substantial proportion of patients (1,5). Laboratory findings commonly reveal markedly elevated C-reactive protein, D-dimer, ferritin, and IL-6 levels accompanied by lymphopenia and cardiac enzyme elevation, reflecting systemic immune activation (3,6). Recent studies have clarified the dysregulated immune mechanisms of MIS-C, emphasizing endothelial activation, T-cell and monocyte hyperresponsiveness, and cytokine-mediated vascular injury.

The immunopathogenesis of MIS-C involves a maladaptive immune activation characterized by polyclonal T-cell expansion, monocyte activation, and a cytokine milieu enriched in IL-6, IL-10, IFN-γ, IL-17A, and CXCL9, indicating a secondary immune-mediated vasculitis rather than direct viral cytopathy (7,8). In contrast, adult patients with severe COVID-19 exhibit a cytokine storm dominated by IL-1β, IL-6, and TNF-α, leading to endothelial dysfunction, microvascular thrombosis, and multiorgan dysfunction (9)

Copyright © 2026 The Author(s). This is an open-access article published by the Federation of Turkish Pathology Societies under the terms of the Creative Commons Attribution License that permits unrestricted use, distribution, and reproduction in any medium or format, provided the original work is properly cited. No use, distribution, or reproduction is permitted that does not comply with these terms.

Correspondence: Meral UNER
Department of Pathology, Hacettepe University Faculty of Medicine, ANKARA, TÜRKİYE
E-mail: bugdayci.meral@gmail.com meral.uner@hacettepe.edu.tr

(10). These findings indicate that while both conditions involve systemic hyperinflammation and endotheliopathy, distinct immune mediators drive tissue injury—MIS-C reflecting a delayed, adaptive response unlike the acute cytokine storm in adults.

Although the clinical and immunologic features of MIS-C have been extensively characterized, the histopathologic spectrum—particularly from tissue biopsies in pediatric patients—remains limited. Most available reports are based on clinical observations or postmortem findings (11,12) (13), and only a small number of well-documented cases have provided detailed morphologic descriptions from pre-mortem specimens (14). Despite this paucity of data, increasing pathological evidence indicates that microvascular inflammation and endothelial injury, together with thrombotic microangiopathy, contribute substantially to tissue damage and organ dysfunction, with findings including myocardial edema, perivascular lymphocytic infiltrates, and fibrin-rich microthrombi observed across multiple organs (11,15).

Histopathologic evaluation of target organs during life or near death offers crucial insight into early immune-mediated injury before irreversible necrosis or infection. This case adds to the limited pre-mortem evidence by documenting endothelial injury, microvascular inflammation, and thrombotic microangiopathy in myocardial and lung biopsies from an infant with confirmed SARS-CoV-2 infection and multisystem failure. These findings link the immunopathologic mechanisms of MIS-C with their early histologic manifestations, bridging clinical and tissue-level understanding.

CASE REPORT

A 9-month-old male infant, born at 35 gestational weeks with a birth weight of 1930 g, was the second child of consanguineous parents (first cousins). At birth, he was diagnosed with esophageal and anal atresia with tracheoesophageal fistula, requiring primary repair and colostomy in the neonatal period. The postoperative course was complicated by Klebsiella sepsis, pleural effusion, and a prolonged neonatal intensive care stay with mechanical ventilation and chest-tube placement.

During follow-up, the patient had recurrent vomiting, abdominal distension, and episodes of gastrointestinal bleeding from the colostomy site. Feeding difficulties necessitated nasogastric support, and despite ongoing care, intermittent regurgitation and respiratory infections persisted under multidisciplinary follow-up.

Three days before admission, the infant became irritable, lethargic, and vomited after each feeding. On presentation, he was febrile (38.8 °C), tachycardic, hypotensive, and hypoxic (SpO_2 70%), with signs of dehydration and poor perfusion. Chest examination showed coarse rales and rhonchi with mild retractions; the abdomen was mildly distended with a functioning colostomy. Laboratory tests revealed metabolic and lactic acidosis, leukocytosis, thrombocytopenia, and elevated inflammatory markers. Nasopharyngeal SARS-CoV-2 PCR was positive, and he was admitted to the pediatric intensive care unit with COVID-19 pneumonia, septic shock, and multiorgan failure.

Chest radiographs showed progressive bilateral alveolo-interstitial opacities and consolidation consistent with COVID-19–related ARDS, without pneumothorax. Abdominal ultrasonography demonstrated normal solid organs but edematous bowel loops around the colostomy, suggesting venous congestion secondary to systemic inflammation and hypoperfusion.

He received antibiotics, fluids, vasopressor, corticosteroid, and bronchodilator therapy. Despite transient improvement, respiratory failure progressed, requiring intubation and ventilation. Within 24 hours, he developed severe hypoxemia and cardiac arrest, and died despite resuscitation. Immediately before death, pre-mortem incisional biopsies were obtained from the myocardium and lung for pathological evaluation.

Sections from the myocardial biopsy revealed myocardial fibers that were variable in size and shape, separated by interstitial edema. Most myocytes showed degenerative changes, including nuclear centralization and perinuclear sarcoplasmic vacuolization. Some myocytes exhibited loss of cross-striations. Within the interstitium, mild edema and scattered lymphocytes were noted (Figure 1A,B). The endothelial cells of small intramyocardial vessels were swollen and vacuolated, indicating endothelial injury. Although no significant inflammatory cell infiltration was seen on routine hematoxylin–eosin sections, occasional interstitial lymphocytes were present. Immunohistochemical staining demonstrated that these lymphocytes were predominantly CD3-positive T cells (Figure 1C), whereas CD20-positive B cells were rare (CD3: clone MRQ-39; EDTA 20'; 1/400; cellmarque. CD20: clone L26; EDTA 20'; predilue; ventana). No viral inclusions or extensive myocyte necrosis were identified. Anti–SARS-CoV-2 immunostaining (rabbit polyclonal SARS-CoV-2 S1; citrate buffer, 10'; 1:300; Abcam, Cambridge, UK) was negative for viral antigen expression. The findings corresponded to acute immune-mediated myocardial injury rather than classic lymphocytic myocarditis.

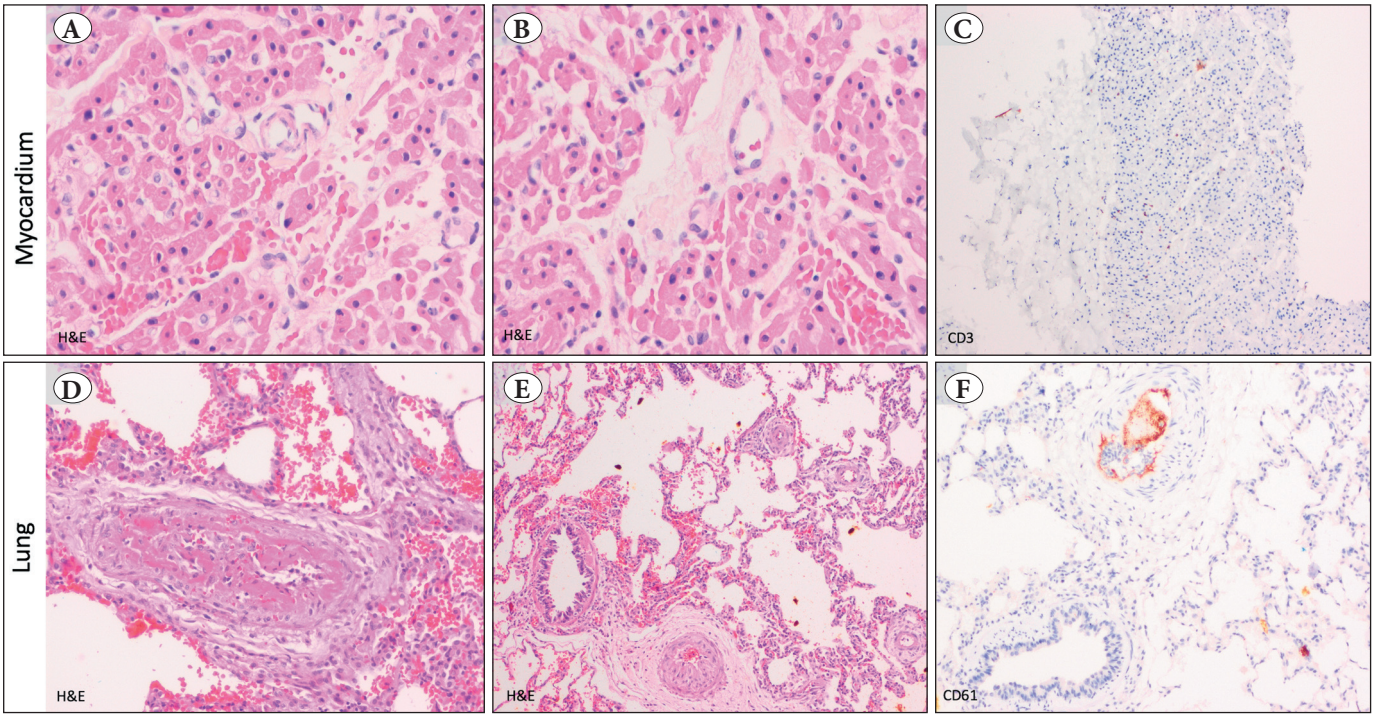

Figure 1: Representative histopathologic and immunohistochemical findings from pre-mortem myocardial and pulmonary biopsies.
Myocardium – A) Myocardial fibers varying in size and shape, separated by mild interstitial edema. Most fibers show degenerative changes, including mild perinuclear sarcoplasmic vacuolization, loss of cross-striations, and nuclear centralization (H&E, ×400).
B) Endothelial cells of small intramyocardial vessels are swollen and vacuolated, indicating endothelial injury (H&E, ×400). **C)** Occasional interstitial lymphocytes are predominantly CD3-positive T cells (IHC, hematoxylin counterstain, ×100); no significant inflammatory cell infiltration is seen on routine hematoxylin–eosin sections.
Lung – D) Intravascular inflammatory cells and fibrin-rich microthrombi within pulmonary vessels, consistent with thrombotic microangiopathy (H&E, ×200). **E)** Pulmonary parenchyma showing reactive endothelial cells lining small vessels containing fragmented erythrocytes and intimal thickening; small bronchi exhibit non-specific changes. Mild perivascular inflammation with sparse interstitial lymphocytes is associated with microthrombotic foci (H&E, ×100). **F)** Immunohistochemical staining for CD61 highlights platelet aggregates and fibrin thrombi within the microvasculature, confirming thrombotic microangiopathy (IHC, hematoxylin counterstain, ×200).

Sections from the lung biopsy showed reactive endothelial cells lining small vessels and capillaries, intravascular inflammatory cells, and fibrin-rich microthrombi in several small-caliber vessels, consistent with thrombotic microangiopathy (Figure 1D,E). Immunohistochemical staining for CD61 (clone 2f2; EDTA 20'; dilution 1/25; Novacastra) highlighted platelet aggregates and fibrin thrombi within the microvasculature (Figure 1F). Alveolar macrophages and interstitial lymphocytes were also present, accompanied by mild interstitial inflammation and focal alveolar hemorrhage. These features reflected endothelial activation and microvascular thrombosis, consistent with COVID-19–associated vasculopathy.

Anti–SARS-CoV-2 immunostaining (rabbit polyclonal SARS-CoV-2 S1; citrate buffer, 10'; 1:300; Abcam, Cambridge, UK) revealed granular cytoplasmic reactivity in alveolar lining epithelial cells and in a subset of respiratory epithelial cells of small bronchi (Figure 2B,C).

Sections from the pleural biopsy demonstrated non-specific findings, including fibrous connective tissue with congested blood vessels and occasional lymphocytes within the stroma. Consistent with the findings in the lung parenchyma, anti–SARS-CoV-2 immunostaining (rabbit polyclonal SARS-CoV-2 S1; citrate buffer, 10'; 1:300; Abcam, Cambridge, UK) showed no evidence of viral antigen expression.

Final diagnoses included myocardial degenerative–edematous changes with endothelial injury, pulmonary thrombotic microangiopathy with mild interstitial inflammation, and pleural vascular congestion with sparse lymphocytes. These findings indicated multifocal endothelial injury and secondary microangiopathy, with mild $CD3^+$ T-cell–predominant inflammation supporting an immune-mediated process consistent with MIS-C in the context of SARS-CoV-2 infection. Clinicopathologic features fulfilled CDC (2023) and WHO (2020) diagnostic criteria for MIS-C, cor-

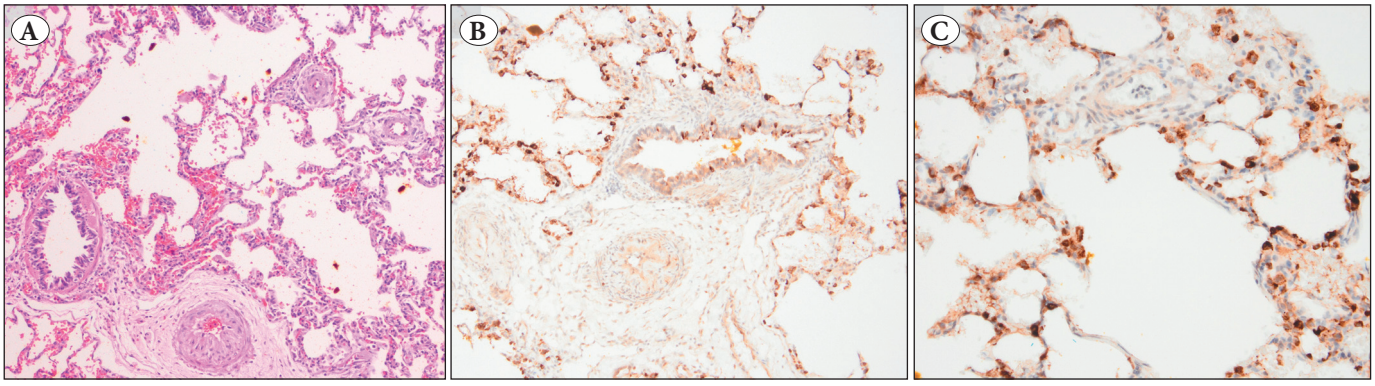

Figure 2: Histopathologic and immunohistochemical findings for SARS-CoV-2 in the lung biopsy.
A) Lung parenchyma with alveolar septa containing small vessels showing intimal thickening, endothelial injury, and occasional fragmented erythrocytes. Alveolar and bronchiolar epithelial cells exhibit non-specific changes (H&E, ×100). **B)** Anti–SARS-CoV-2 immunohistochemistry demonstrating granular cytoplasmic positivity in alveolar lining epithelial cells and in respiratory epithelial cells lining small bronchi (IHC, hematoxylin counterstain, ×100). **C)** Higher-magnification view confirming cytoplasmic immunoreactivity in alveolar lining cells, whereas fibroblasts and vascular endothelial cells within the septa remain negative (IHC, hematoxylin counterstain, ×200).

roborated by histopathologic evidence of endothelial and microvascular injury (Table I).

DISCUSSION

Multisystem Inflammatory Syndrome in Children (MIS-C) is a postinfectious hyperinflammatory disorder that typically develops several weeks after SARS-CoV-2 infection. Large multicenter studies have demonstrated predominant cardiac and gastrointestinal involvement (up to 80–90% and 70–80%, respectively), with 60–80% of patients requiring intensive care and a mortality rate of 1–4% (4,16,17) (18). Laboratory abnormalities commonly include markedly elevated C-reactive protein, D-dimer, ferritin, and IL-6, reflecting systemic immune activation (4,19).

Our patient presented with persistent fever, multiorgan dysfunction, and rapid cardiovascular deterioration, consistent with these features. However, unlike the typical MIS-C population, this case occurred in an infant with developmental anomalies and prior surgical history associated with potential immune suppression, which may have contributed to a more severe clinical course.

MIS-C shares clinical features with Kawasaki disease and toxic shock syndrome, but differs in age distribution, extent of cardiac involvement, and cytokine profile (20). It is characterized by a cytokine milieu enriched in IL-6, IL-10, and IFN-γ, distinct from the IL-1β and TNF-α predominance seen in acute infection (7,20–22). Unlike severe acute COVID-19, MIS-C represents a delayed immune dysregulation with limited viral replication and exaggerated adaptive immune activation (19). Although this case occurred at an age more suggestive of Kawasaki disease, the timing of presentation and the histopathologic findings—marked by endothelial injury and thrombotic microangiopathy rather than direct viral cytopathy—support a secondary immune-mediated process consistent with MIS-C (17).

At the tissue level, MIS-C reflects a dysregulated immune response in which endothelial activation, cytokine-mediated inflammation, and microvascular thrombosis act together to produce tissue injury, with thrombotic microangiopathy representing a key morphologic correlate of this process (7,23,24). Autopsy studies support this concept: viral antigen has been demonstrated in endothelial cells in pediatric COVID-19 (11), while myocardial edema, lymphocytic infiltration, and fibrin-rich microthrombi have been reported across multiple organs (12,15,23). Together, these findings suggest that vascular injury in MIS-C is predominantly immune-mediated, although focal viral effects may coexist.

In the presented patient, pre-mortem myocardial and lung biopsies demonstrated endothelial swelling, cytoplasmic vacuolization, and platelet–fibrin microthrombi, consistent with thrombotic microangiopathy. These findings resemble those reported in MIS-C but were less extensive, likely reflecting an earlier disease stage. Immunohistochemical staining for CD61 confirmed platelet-fibrin aggregates, supporting localized thromboinflammatory activation. Viral antigen was absent in the myocardium and pleura but present in respiratory epithelium, suggesting that extrapulmonary injury was primarily immune-mediated rather than due to direct viral cytopathy.

Table I: Evaluation of MIS-C Diagnostic Criteria in the Present Case According to CDC (2023) and WHO (2020) Definitions (1,2).

Criterion	CDC (2023) Definition	WHO (2020) Definition	Findings in the Present Case	Criterion Met
Age	< 21 years	0–19 years	9-month-old male infant	Yes
Fever	Subjective or documented fever ≥38.0°C	Fever ≥3 days	Documented fever (38.8°C) for 3 days prior to admission	Yes
Evidence of SARS-CoV-2 infection	Positive PCR, antigen, or serology for SARS-CoV-2	Evidence of COVID-19 infection or contact	Positive nasopharyngeal SARS-CoV-2 PCR	Yes
Inflammation markers	Elevated CRP (≥3 mg/dL), ESR, fibrinogen, procalcitonin, D-dimer, ferritin, LDH, IL-6, or neutrophilia	Elevated markers of inflammation (ESR, CRP, procalcitonin, etc.)	Markedly elevated CRP, D-dimer, lactate, ferritin; leukocytosis and thrombocytopenia	Yes
Multisystem (≥2) involvement	≥2 organ systems affected (cardiac, renal, respiratory, hematologic, gastrointestinal, dermatologic, neurological)	Involvement of ≥2 organ systems	Cardiac: tachycardia, hypotension, endothelial injury, myocardial degeneration. Respiratory: ARDS, alveolar microthrombi. GI: vomiting, melena, distension. Hematologic: thrombocytopenia.	Yes
Cardiac involvement	Elevated troponin/BNP, myocarditis, pericarditis, coronary abnormalities, arrhythmia, or ventricular dysfunction	Same	Myocardial biopsy: degenerative myocyte changes, endothelial injury, mild T-cell infiltrate; consistent with immune-mediated myocardial injury	Yes
Respiratory involvement	Pulmonary infiltrates, ARDS, or hypoxemia	Part of multisystem inflammation	Bilateral alveolo-interstitial opacities; fibrin-platelet microthrombi and alveolar hemorrhage	Yes
Hematologic involvement	Thrombocytopenia, coagulopathy, or elevated D-dimer	Same	Thrombocytopenia and microvascular thrombosis consistent with thrombotic microangiopathy	Yes
Gastrointestinal involvement	Abdominal pain, vomiting, diarrhea	Same	Persistent vomiting, abdominal distension, melena	Yes
Exclusion of alternative causes	No alternative plausible diagnosis (e.g., bacterial sepsis, toxic shock)	No other microbial cause of inflammation	Bacterial cultures negative; no histologic features of bacterial sepsis	Yes
Histopathologic correlation	Not required (supportive)	Not required (supportive)	Pre-mortem biopsies showing endothelial injury, thrombotic microangiopathy, T-cell–dominant inflammation without viral cytopathy	Supportive evidence

CDC: Centers for Disease Control and Prevention, **WHO:** World Health Organization, **PCR:** Polymerase Chain Reaction, **SARS-CoV-2:** Severe Acute Respiratory Syndrome Coronavirus 2, **ARDS:** Acute Respiratory Distress Syndrome, **BNP:** B-type Natriuretic Peptide, **CRP:** C-reactive Protein, **ESR:** Erythrocyte Sedimentation Rate, **LDH:** Lactate Dehydrogenase.

Although lymphocytic infiltration was mild, the predominance of $CD3^+$ T cells suggests a T-cell–mediated immune response consistent with MIS-C (7). This pattern aligns with the cytokine profile observed in MIS-C, and supports immune-mediated vascular inflammation as a contributor to tissue injury.

Pre-mortem histopathologic data in MIS-C remain limited, as most reports are based on autopsy material (11,12). Our case captures an earlier phase of endothelial injury and microvascular inflammation before irreversible tissue damage, such as necrosis or severe ischemic change. The coexistence of pulmonary viral antigen and extrapulmonary immune-

mediated injury highlights the multiphasic nature of MIS-C and underscores the diagnostic value of early biopsy.

In conclusion, this infant-onset, biopsy-confirmed MIS-C–like case provides rare pre-mortem evidence of endothelial injury and thrombotic microangiopathy as early morphologic correlates of immune-mediated vasculopathy. The findings emphasize MIS-C as a vascular inflammatory phenotype linking pediatric and adult COVID-19–associated endotheliopathy and highlight the importance of recognizing these features for early diagnosis and potential endothelial-targeted therapy.

Conflict of Interest
The authors declare that they have no conflicts of interest to disclose.

Funding
No funding was received for this study.

Ethical Approval
Ethics committee approval was not applicable for this case report. Informed consent was obtained from the patient's parents, and all efforts were made to ensure patient anonymity and data confidentiality.

Authorship Contributions
Concept: **MU, DO,** Design: **MU,** Data collection and/or processing: **MU, SK, FA,** Analysis and/or interpretation: **MU, DO,** Literature search: **MU,** Writing: **MU,** Approval: **All authors.**

REFERENCES

1. Centers for Disease Control and Prevention. Multisystem Inflammatory Syndrome in Children (MIS-C) Associated with SARS-CoV-2 Infection: Case Definition Information for Healthcare Providers. 2023. Available from: https://www.cdc.gov
2. World Health Organization. Multisystem inflammatory syndrome in children and adolescents temporally related to COVID-19. 2020. Available from: https://www.who.int
3. Nakra N, Blumberg D, Herrera-Guerra A, Lakshminrusimha S. Multi-system inflammatory syndrome in children (MIS-C) following SARS-CoV-2 infection: review of clinical presentation, hypothetical pathogenesis, and proposed management. Children (Basel). 2020;7(7):69. PMID: 32630212 DOI: 10.3390/children7070069
4. Feldstein LR, Rose EB, Horwitz SM, Collins JP, Newhams MM, Son MBF, Newburger JW, Kleinman LC, Heidemann SM, Martin AA, Singh AR, Li S, Tarquinio KM, Jaggi P, Oster ME, Zackai SP, Gillen J, Ratner AJ, Walsh RF, Fitzgerald JC, Keenaghan MA, Alharash H, Doymaz S, Clouser KN, Giuliano JS Jr, Gupta A, Parker RM, Maddux AB, Havalad V, Ramsingh S, Bukulmez H, Bradford TT, Smith LS, Tenforde MW, Carroll CL, Riggs BJ, Gertz SJ, Daube A, Lansell A, Coronado Munoz A, Hobbs CV, Marohn KL, Halasa NB, Patel MM, Randolph AG; Overcoming COVID-19 Investigators; CDC COVID-19 Response Team. Multisystem inflammatory syndrome in U.S. children and adolescents. N Engl J Med. 2020;383(4):334-46. PMID: 32598831 DOI: 10.1056/NEJMoa2021680
5. Molloy EJ, Nakra N, Gale C, Dimitriades VR, Lakshminrusimha S. Multisystem inflammatory syndrome in children (MIS-C) and neonates (MIS-N) associated with COVID-19: optimizing definition and management. Pediatr Res. 2023;93(6):1499-508. PMID: 37308164 DOI: 10.1038/s41390-023-02603-0
6. Gurlevik SL, Ozsurekci Y, Sağ E, Derin Oygar P, Kesici S, Akca ÜK, Cuceoglu MK, Basaran O, Göncü S, Karakaya J, Cengiz AB, Özen S. The difference of the inflammatory milieu in MIS-C and severe COVID-19. Pediatr Res. 2022;92(6):1805-14. PMID: 35976355 DOI: 10.1038/s41390-022-02315-z
7. Consiglio CR, Cotugno N, Sardh F, Pou C, Amodio D, Rodriguez L, Tan Z, Zicari S, Ruggiero A, Pascucci GR, Santilli V, Campbell T, Bryceson Y, Eriksson D, Wang J, Marchesi A, Lakshmikanth T, Campana A, Villani A, Rossi P; CACTUS Study Team; Landegren N, Palma P, Brodin P. The immunology of multisystem inflammatory syndrome in children with COVID-19. Cell. 2020;183(4):968-81.e7. PMID: 33010817 DOI: 10.1016/j.cell.2020.09.016
8. Gruber CN, Patel RS, Trachtman R, Lepow L, Amanat F, Krammer F, Wilson KM, Onel K, Geanon D, Tuballes K, Patel M, Mouskas K, O'Donnell T, Merritt E, Simons NW, Barcessat V, Del Valle DM, Udondem S, Kang G, Gangadharan S, Ofori-Amanfo G, Laserson U, Rahman A, Kim-Schulze S, Charney AW, Gnjatic S, Gelb BD, Merad M, Bogunovic D. Mapping systemic inflammation and antibody responses in multisystem inflammatory syndrome in children (MIS-C). Cell. 2020;183(4):982-95.e14. PMID: 33010818 DOI: 10.1016/j.cell.2020.09.034
9. Fajgenbaum DC, June CH. Cytokine storm. N Engl J Med. 2020;383(23):2255-73. PMID: 33264547 DOI: 10.1056/NEJMra2026131
10. Mbonde AA, O'Carroll CB, Grill MF, Zhang N, Butterfield R, Demaerschalk BM. Stroke features, risk factors, and pathophysiology in SARS-CoV-2–infected patients. Mayo Clin Proc Innov Qual Outcomes. 2022;6(2):156-65. PMID: 35281922 DOI: 10.1016/j.mayocpiqo.2021.11.010
11. Duarte-Neto AN, Caldini EG, Gomes-Gouvêa MS, Kanamura CT, de Almeida Monteiro RA, Ferranti JF, Ventura AMC, Regalio FA, Fiorenzano DM, Gibelli MABC, Carvalho WB, Leal GN, Pinho JRR, Delgado AF, Carneiro-Sampaio M, Mauad T, Ferraz da Silva LF, Saldiva PHN, Dolhnikoff M. An autopsy study of the spectrum of severe COVID-19 in children: from SARS to different phenotypes of MIS-C. EClinicalMedicine. 2021;35:100850. PMID: 33987838 DOI: 10.1016/j.eclinm.2021.100850
12. Beaudry JT, Dietrick B, Lammert DB, Constas A, McCaw J, Hammond J, Buendia M, Stein JE, Pekosz A, Schuette J, Mostafa HH, Hooper JE, Bernier M, Agwu A, Feldman LS. Fatal SARS-CoV-2 inflammatory syndrome and myocarditis in an adolescent: a case report. Pediatr Infect Dis J. 2021;40(2):e72-6. PMID: 33394778 DOI: 10.1097/INF.0000000000003021
13. Taweevisit M, Chindamporn A, Sujjavorakul K, Samransamruajkit R, Thorner PS. Multisystem inflammatory syndrome in children (MIS-C) showing disseminated aspergillosis, cytomegalovirus reactivation and persistent SARS-CoV-2: case report with autopsy review. Pathol Res Pract. 2022;238:154106. PMID: 35917483 DOI: 10.1016/j.prp.2022.154106

14. Maruyama K, Yasuda K, Ito R, Imanaka-Yoshida K. Histopathological findings of pericarditis in a patient with multisystem inflammatory syndrome in children associated with COVID-19: a case report. Pathol Int. 2023;73(2):91-6. PMID: 36395846 DOI: 10.1111/pin.13286
15. Dolhnikoff M, Ferreira Ferranti J, de Almeida Monteiro RA, Duarte-Neto AN, Soares Gomes-Gouvêa M, Viu Degaspare N, Figueiredo Delgado A, Montanari Fiorita C, Nunes Leal G, Rodrigues RM, Taverna Chaim K, Rebello Pinho JR, Carneiro-Sampaio M, Mauad T, Ferraz da Silva LF, Brunow de Carvalho W, Saldiva PHN, Garcia Caldini E. SARS-CoV-2 in cardiac tissue of a child with COVID-19-related multisystem inflammatory syndrome. Lancet Child Adolesc Health. 2020;4(10):790-4. PMID: 32805210 DOI: 10.1016/S2352-4642(20)30257-1
16. Feldstein LR, Tenforde MW, Friedman KG, Newhams M, Rose EB, Dapul H, Soma VL, Maddux AB, Mourani PM, Bowens C, Maamari M, Hall MW, Riggs BJ, Giuliano JS Jr, Singh AR, Li S, Kong M, Schuster JE, McLaughlin GE, Schwartz SP, Walker TC, Loftis LL, Hobbs CV, Halasa NB, Doymaz S, Babbitt CJ, Hume JR, Gertz SJ, Irby K, Clouser KN, Cvijanovich NZ, Bradford TT, Smith LS, Heidemann SM, Zackai SP, Wellnitz K, Nofziger RA, Horwitz SM, Carroll RW, Rowan CM, Tarquinio KM, Mack EH, Fitzgerald JC, Coates BM, Jackson AM, Young CC, Son MBF, Patel MM, Newburger JW, Randolph AG; Overcoming COVID-19 Investigators. Characteristics and outcomes of US children and adolescents with multisystem inflammatory syndrome in children (MIS-C) compared with severe acute COVID-19. JAMA. 2021;325(11):1074-87. PMID: 33625505 DOI: 10.1001/jama.2021.2091
17. Godfred-Cato S, Bryant B, Leung J, Oster ME, Conklin L, Abrams J, Roguski K, Wallace B, Prezzato E, Koumans EH, Lee EH, Geevarughese A, Lash MK, Reilly KH, Pulver WP, Thomas D, Feder KA, Hsu KK, Plipat N, Richardson G, Reid H, Lim S, Schmitz A, Pierce T, Hrapcak S, Datta D, Morris SB, Clarke K, Belay E; California MIS-C Response Team. COVID-19-associated multisystem inflammatory syndrome in children—United States, March–July 2020. MMWR Morb Mortal Wkly Rep.2020;69(32):1074-80. PMID: 32790663 DOI: 10.15585/mmwr.mm6932e2
18. Ozsurekci Y, Gürlevik S, Kesici S, Akca UK, Oygar PD, Aykac K, Karacanoglu D, Sarıtas Nakip O, Ilbay S, Katlan B, Ertugrul İ, Cengiz AB, Basaran O, Cura Yayla BC, Karakaya J, Bilginer Y, Bayrakci B, Ceyhan M, Ozen S. Multisystem inflammatory syndrome in children during the COVID-19 pandemic in Turkey: first report from the Eastern Mediterranean. Clin Rheumatol.2021;40(8):3227-37. PMID: 33825080 DOI: 10.1007/s10067-021-05604-8
19. Reynolds D, Davies P. Post COVID-19 paediatric inflammatory syndrome (PIMS-TS/MIS-C): what have we learned? Paediatr Child Health. 2025;35(7):247-52.
20. Godfred-Cato S, Abrams JY, Balachandran N, Jaggi P, Jones K, Rostad CA, Lu AT, Fan L, Jabbar A, Anderson EJ, Kao CM, Hunstad DA, Rosenberg RB, Zafferani MJ, Ede KC, Ballan W, Laham FR, Beltran Y, Bryant B, Meng L, Hammett TA, Oster ME, Bamrah Morris S, Belay ED. Distinguishing multisystem inflammatory syndrome in children from COVID-19, Kawasaki disease and toxic shock syndrome. Pediatr Infect Dis J.2022;41(4):315-23. PMID: 35271437 DOI: 10.1097/INF.0000000000003477
21. Sharma C, Ganigara M, Galeotti C, Burns J, Berganza FM, Hayes DA, Singh-Grewal D, Bharath S, Sajjan S, Bayry J. Multisystem inflammatory syndrome in children and Kawasaki disease: a critical comparison. Nat Rev Rheumatol. 2021;17(12):731-48. PMID: 34526579 DOI: 10.1038/s41584-021-00709-9
22. Rowley AH. Understanding SARS-CoV-2-related multisystem inflammatory syndrome in children. Nat Rev Immunol.2020;20(8):453-4. PMID: 32488254 DOI: 10.1038/s41577-020-0367-5
23. Diorio C, McNerney KO, Lambert M, Paessler M, Anderson EM, Henrickson SE, Chase J, Liebling EJ, Burudpakdee C, Lee JH, Balamuth FB, Blatz AM, Chiotos K, Fitzgerald JC, Giglia TM, Gollomp K, Odom John AR, Jasen C, Leng T, Petrosa W, Vella LA, Witmer C, Sullivan KE, Laskin BL, Hensley SE, Bassiri H, Behrens EM, Teachey DT. Evidence of thrombotic microangiopathy in children with SARS-CoV-2 across the spectrum of clinical presentations. Blood Adv.2020;4(23):6051-63. PMID: 33347714 DOI: 10.1182/bloodadvances.2020003471
24. Buszko M, Nita-Lazar A, Park JH, Schwartzberg PL, Verthelyi D, Young HA, Rosenberg AS. Lessons learned: new insights on the role of cytokines in COVID-19. Nat Immunol. 2021;22(4):404-11. PMID: 33767146 DOI: 10.1038/s41590-021-00901-9