doi: 10.5146/tjpath.2026.15045

Acinar Salivary Gland Choristoma in the Mammary Gland in a Patient with Gynecomastia: A Rare Finding, Diagnostic Considerations, and Review of Published Evidence

Cynthia MONROY-RAMOS[1], Carlos ORTIZ-HIDALGO[1,2]

[1]*Department of Anatomic Pathology, Fundación Clínica Médica Sur, Mexico City, Mexico*
[2]*Department of Tissue and Cell Biology, Universidad Panamericana, School of Medicine, Mexico City, Mexico*

Turk Patoloji Derg 2026, 42:I-IV **Received:** 21.12.2025 **Accepted:** 23.06.2026 **Published Online:** 02.10.2026

ABSTRACT

To report a case of salivary gland choristoma in a patient with gynecomastia. While it is commonly found in the head and neck region, its occurrence in the breast is exceedingly rare. We report a unique case in which a salivary gland acinar choristoma was incidentally identified in a 43-year-old man who underwent surgery for gynecomastia.

Histological examination revealed typical features of gynecomastia along with a well-circumscribed area composed exclusively of salivary acini, with no ductal structures and no continuity with adjacent breast epithelium. Immunohistochemical staining confirmed acinar differentiation with positivity for α-amylase, S100, SOX10, and DOG1 expression. The absence of epithelial continuity supports a choristomatous rather than a metaplastic origin.

Only two cases of salivary gland choristoma in breast tissue have been reported in the literature. These findings underscore the potential plasticity of mammary cells and the importance of considering salivary gland choristoma in the differential diagnosis of unusual breast lesions. Accurate diagnosis requires careful histopathological and immunohistochemical evaluation to differentiate these lesions from neoplastic processes with similar morphology.

Keywords: Choristoma, Breast, Salivary gland, Gynecomastia

INTRODUCTION

Choristoma, also known as heterotopia, refers to the presence of histologically normal, mature, and benign tissue in an abnormal anatomical site. Although not considered true tumors, they may be mistaken for neoplasms (1,2). Choristomas have been described in various organs, most commonly in the head and neck region (3). However, they are exceedingly rare in the mammary gland. Reported cases have included ectopic tissues—such as cartilaginous or thyroid tissues—that are associated with both carcinoma and benign breast lesions (4,5). To date, only two cases of salivary gland choristoma in the breast have been reported in the English-language literature. Here, we describe a case of a choristoma composed of salivary gland acini in a patient with gynecomastia (5,6).

CASE REPORT

A 43-year-old man presented with gynecomastia and subsequently underwent surgical resection. Histological examination revealed mammary parenchyma with abundant fibrous stroma and an increased number of ducts displaying characteristic three-layered epithelium: an inner luminal layer, an intermediate layer of cuboidal-to-columnar cells, and an outer myoepithelial cell layer. The ducts showed irregular branching and mild-to-moderate epithelial hyperplasia and were surrounded by a cellular, myxoid, and edematous stroma. Some ducts displayed papillary or cribriform architecture, and focal pseudoangiomatous stromal hyperplasia (PASH) was also noted. These histological findings were consistent with gynecomastia.

Incidentally, a 2.5-mm nodule was found, consisting of numerous acini morphologically identical to those of the salivary gland (Figure 1A). These acini were formed by large, pyramidal cells with basally located nuclei and abundant eosinophilic, granular cytoplasm (Figure 1B) and showed positivity for periodic acid–Schiff (PAS) staining (Figure 1C). The proliferation was embedded within abundant adipose tissue and was composed exclusively of acini, with no

Copyright © 2026 The Author(s). This is an open-access article published by the Federation of Turkish Pathology Societies under the terms of the Creative Commons Attribution License that permits unrestricted use, distribution, and reproduction in any medium or format, provided the original work is properly cited. No use, distribution, or reproduction is permitted that does not comply with these terms.

Correspondence: Carlos ORTIZ-HIDALGO
Department of Anatomic Pathology, Fundación Clínica Médica Sur, Mexico City, Mexico
E-mail: ortizhidalgocarlos@gmail.com Phone: +52 555 453 20 07

ducts identified. Immunohistochemically, the acinar cells were positive for α-amylase, DOG1, SOX10, and S100 protein expression, as well as actin expression in the myoepithelial cells (Figure 2). Based on these findings, a diagnosis of salivary gland acinar choristoma was established.

DISCUSSION

The mammary gland and salivary glands share notable similarities from an evolutionary and comparative standpoint, as they are analogous exocrine glands with similar structural patterns (7). They originate from the surface ectoderm during embryonic development and exhibit a similar histological architecture as compound tubuloalveolar glands do. In addition to having branched excretory duct systems, both contain myoepithelial cells that facilitate the expulsion of glandular contents. They also exhibit similarities in terms of their secretory mechanisms: salivary glands use merocrine secretion, whereas mammary glands combine merocrine secretion (for proteins such as casein) with apocrine secretion (for lipid components) (8).

The morphological finding that supported the diagnosis of choristoma in our patient was the absence of any apparent continuity between the salivary gland cells and the adjacent mammary epithelium. By contrast, metaplasia, defined as the reversible replacement of one type of adult cell by another in response to environmental or pathological stimuli, typically presents in continuity with ductal or lobular epithelium and is often associated with proliferative or neoplastic processes. In our patient, the salivary gland tissue was well demarcated, circumscribed, and surrounded by adipose tissue, with no connection to the surrounding mammary tissue—supporting the interpretation of a choristoma.

Regarding the histogenesis of choristomas, two hypotheses have been proposed: 1) the presence of tissue remnants originating during embryogenesis, interpreted as the result of migration and settlement of a cellular primordium in an ectopic site during development; and 2) metaplasia induced by trauma or chronic inflammation, originating from pluripotent mesenchymal cells (9). Various meta-

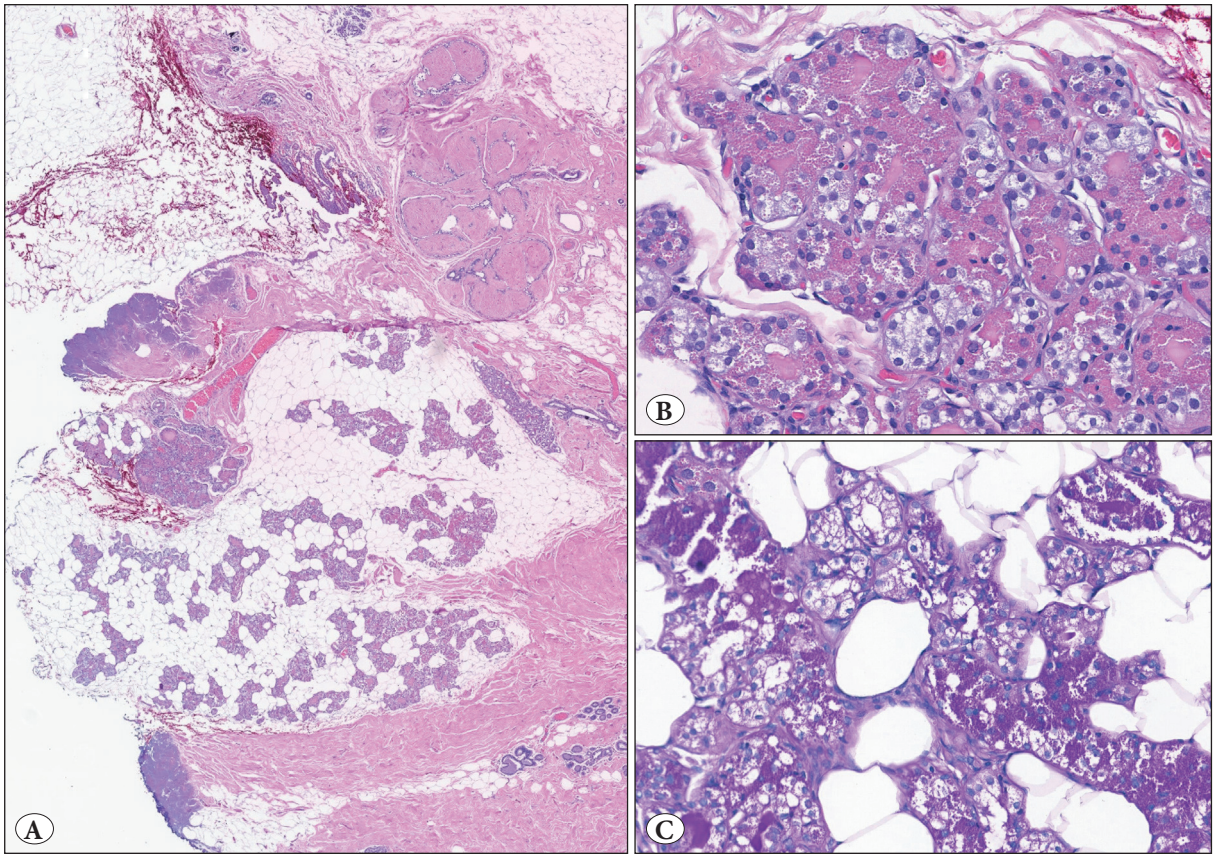

Figure 1: A) Low-power view of the breast biopsy showing a well-circumscribed nodule within adipose-rich breast tissue, corresponding to a salivary gland choristoma. In the lower left corner, there is a cluster of florid ductal proliferations with pseudo-lobular architecture rather than true terminal duct lobular units (x40). **B)** Higher magnification reveals salivary acinar cells, which in **C)** show PAS-positive staining (x200).

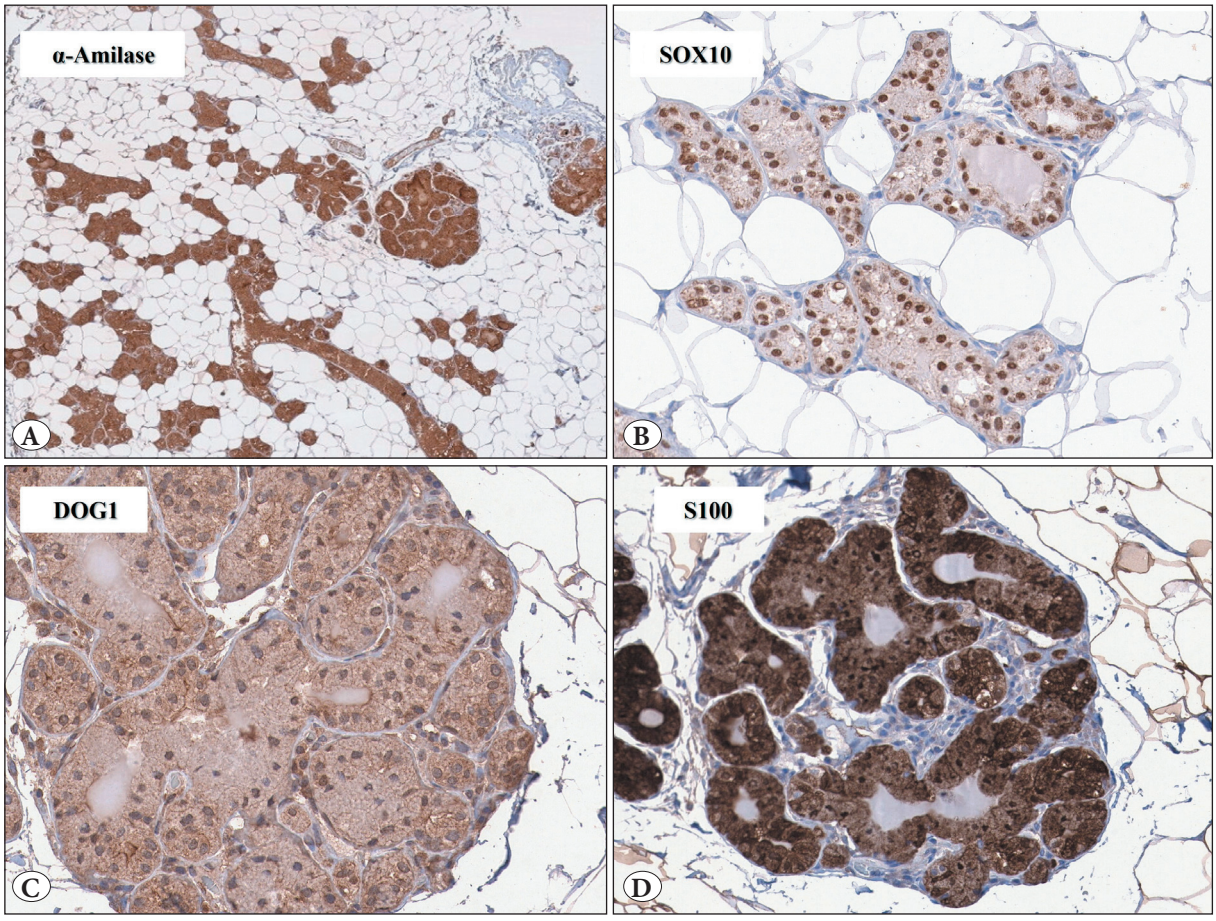

Figure 2: Salivary gland choristoma immunohistochemistry. **A)** Salivary gland acini show positivity for α-amylase, **B)** SOX11, **C)** DOG1, and **D)** S-100 protein expression (x200).

plastic changes in the mammary gland that alter the usual glandular phenotype, such as squamous, apocrine, or mucinous metaplasia, have been described. Some authors have suggested that the origin of certain breast tumors—such as adenoid cystic or mucoepidermoid carcinomas—could be explained through this mechanism (10,11).

Additionally, the concept of transdifferentiation—which often overlaps with metaplasia or, in certain contexts, is considered a specific form of metaplasia—refers to the ability of a differentiated cell to change its lineage into another cell type without forming an intermediate progenitor or pluripotent state (12). In mammary tissues, it has been proposed that under certain microenvironmental conditions or in the presence of genomic alterations the plasticity of epithelial and myoepithelial cells can lead to the acquisition of an acinar phenotype similar to that of the salivary gland (13). This mechanism could explain not only the appearance of tumors with salivary-type differentiation but also the formation of true choristomas (6,7). Additionally, when cocultured with mammary epithelial organoids, mature adipocytes lose their adipocytic phenotype and acquire epithelial characteristics, including the expression of milk proteins such as whey acidic protein and β-casein (14).

To date, only two well-documented cases of salivary gland choristoma in the breast have been reported in the medical literature (Table I). In 2009, Matoso et al. reported the case of a 62-year-old woman treated with neoadjuvant chemotherapy for infiltrating ductal carcinoma; in a subsequent biopsy, the carcinoma was absent, but a lobe of salivary gland-like acinar differentiation was incidentally identified in the background of benign breast tissue (5). In a case published by Maffini et al. in 2011, an ectopic normal salivary gland showing acinar structures with mucous secretion and intercalated ducts surrounded by fibrous tissue was found within the mammary parenchyma in a 45-year-old woman with infiltrating duct carcinoma (6).

These reports raise the possibility of a plastic potential of mammary cells to adopt uncommon phenotypes—such as the salivary acinar type—and highlight the relevance of these findings within the spectrum of breast tumors with

Table I: Reported cases of mammary choristoma in the literature.

Case	Diagnosis	Choristoma	References
1	A 62-year-old woman was treated with neoadjuvant chemotherapy for infiltrating ductal carcinoma of the left breast. Subsequently, the patient exhibited complete response and absence of carcinoma.	A lobe of salivary gland-like acinar differentiation was incidentally identified in the background of benign breast tissue.	Matoso et al. (5)
2	A 66-year-old woman presented with infiltrating ductal carcinoma of the left breast.	An aggregate of salivary gland tissue composed of pure serous acinar glands with terminal and intercalated ducts, similar to those of salivary glands	Maffini et al. (6)
3	A 43-year-old man presented with gynecomastia.	A 2.5 mm nodule composed of numerous acini morphologically indistinguishable from those of the salivary gland	Present case

salivary gland–type differentiation. They also reinforce the notion that mammary tissue has a broader differentiation potential than the usual glandular phenotype does, suggesting the occurrence of cellular plasticity or transdifferentiation phenomena under certain microenvironmental conditions (15).

Given the rarity of this finding, it is essential that pathologists consider salivary gland choristoma in the differential diagnosis of unusual breast lesions with histological features resembling those of salivary tissue. A precise diagnosis generally requires the integration of histopathological and immunohistochemical findings to distinguish these lesions from other neoplastic processes with similar morphology.

Conflict of Interest
The authors declare no conflict of interest.

Funding
This work did not receive funding.

Authorship Contributions
Concept: **CMR, COH,** Design: **CMR, COH,** Data collection or processing: **CMR, COH,** Analysis or Interpretation: **CMR, COH,** Literature search: **CMR, COH,** Writing: **CMR, COH,** Approval: **COH.**

REFERENCES

1. Batsakis JG. Pathology consultation. Nomenclature of developmental tumors. Ann Otol Rhinol Laryngol. 1984;93(1 Pt 1):98-9. doi: 10.1177/000348948409300122
2. Ozolek JA, Tekkesin MS. THE "-OMAS" and "-OPIAS": targeted and philosophical considerations regarding hamartomas, choristomas, teratomas, ectopias, and heterotopias in pediatric otorhinolaryngologic pathology. Head Neck Pathol. 2021;15(1):25-40. doi: 10.1007/s12105-020-01251-y.
3. Semwal S, Joshi D, Gupta V, Kapoor N. Cartilaginous choristoma of tongue: A rare case report. J Oral Maxillofac Pathol. 2019;23(Suppl 1):40-42. doi:10.4103/jomfp.JOMFP_24_18.
4. Metcalf JS, Ellis B. Choristoma of the breast. Hum Pathol. 1985;16(7):739-40. doi:10.1016/S0046-8177(85)80161-1.
5. Matoso A, Easley SE, Gnepp DR, Mangray S. Salivary gland acinar-like differentiation of the breast. Histopathology. 2009;54(2):262-3. doi: 10.1111/j.1365-2559.2008.03205.x.
6. Maffini F, Pisa E, Possanzini P, Viale G. Salivary gland choristoma of breast. Breast J. 2012;18(2):181. doi: 10.1111/j.1524-4741.2011.01210.x.
7. Ganga BV, Ramachandrappa K, Shamanna K. A systemic review on similarities between salivary and mammary gland neoplasms and the role of antihormonal therapy in salivary gland tumors. Int J Head Neck Surg. 2023;14(2):21–32. doi:10.5005/jp-journals-10001-1549
8. Triantafyllou A, Hunt JL, Devaney KO, Ferlito A. A perspective of comparative salivary and breast pathology. Part I: microstructural aspects, adaptations and cellular events. Eur Arch Otorhinolaryngol. 2014;271:647-63. doi: 10.1007/s00405-013-2488-y.
9. Slack JM, Tosh D. Transdifferentiation and metaplasia--switching cell types. Curr Opin Genet Dev. 2001;11(5):581-6. doi: 10.1016/s0959-437x(00)00236-7.
10. Sun HA, Lee WT, Hsu HJ. Lingual osteoma-a case report and literature review. Ear Nose Throat J. 2022;101(10):647-9. doi: 10.1177/0145561320977469.
11. McMullen ER, Zoumberos NA, Kleer CG. Metaplastic breast carcinoma: update on histopathology and molecular alterations. Arch Pathol Lab Med. 2019;143(12):1492-6. doi: 10.5858/arpa.2019-0396-RA.
12. Mishra P, Biesiada I, Gupta P, Ghavami S, Markowski J, Łos MJ. Unraveling the complexity and advancements of transdifferentiation technologies in the biomedical field and their potential clinical relevance. Arch Immunol Ther Exp (Warsz). 2024;73(1). doi: 10.2478/aite-2025-0001.
13. Rosciani AS, Merlo WA, Insfrán RM, Benítez JS, Ortega HH. Role of myoepithelial cells in the development of complex and mixed tumors of the canine mammary gland. Revista Veterinaria. 2021;32(1):1-10. doi:10.30972/vet.2111844
14. Perugini J, Smorlesi A, Acciarini S, Mondini E, Colleluori G, Pirazzini C, Kwiatkowska KM, Garagnani P, Franceschi C, Zingaretti MC, Dani C, Giordano A, Cinti S. Adipo-epithelial transdifferentiation in in vitro models of the mammary gland. Cells. 2024;13(11):943. doi: 10.3390/cells13110943.
15. Tosh D, Slack JM. How cells change their phenotype. Nat Rev Mol Cell Biol. 2002;3(3):187-94. doi: 10.1038/nrm761. PMID: 11994739.