

'GIANT' HEMANGIOMA OF THE LIVER (a case report)

Dr. Nadir Paksoy*

ÖZET: Olağandışı büyüklükte bir karaciğer hemangiyom'u ('dev' hemangiyom) olgusu: Hemangiyom karaciğerin damarsal kökenli selim bir tümördür. Genellikle 2-3 cm çapında olup herhangi bir klinik belirti ve bulgu göstermeksizin, tesadüfen laparoskopi veya otopsi sırasında saptanır. Histopatolojik olarak 'kavemöz hemangiyom' özellikleri gösterir. Öte yandan, büyük boyutlara ulaşan ve klinik belirti-bulgu gösteren 'dev' hemangiyom adıyla anılan türleri de vardır. Bunlar çok nadir görülür. Bu yazıda, Pasifik Okyanusu'ndaki Samoa Adaları'nda patoloji uzmanı olarak çalıştığım sırada, 43 yaşındaki yerli bir kadında saptadığımız; 15 x 13 x 5 cm gibi olağan dışı büyüklük gösteren bir karaciğer 'dev' hemangiyom'u olgusu sunuldu. Bu konudaki yayınların ışığında klinik, patoloji ve tedaviyle ilgili özellikleri tartışıldı.

SUMMARY: 'Giant' Hemangioma of the liver: A case report: Hemangioma of the liver is a benign tumor of vascular origin. Most of them are less than 2-3 cm. in diameter and remain asymptomatic. Although hemangioma is the most frequent benign tumor of the liver, large symptomatic hemangiomas, so-called 'giant' hemangiomas, are rare. In this paper, such a case of 'giant' hepatic hemangioma measuring 15 cm. in diameter, seen in a middle-aged Samoan woman, is presented. Clinical, pathological and therapeutical features were discussed.

INTRODUCTION

Hemangioma of the liver is a benign tumor of vascular origin. It is usually of the cavernous type and may be solitary or multiple. In children a capillary pattern may be seen. Most of them are less than 2 cm. in diameter and remain asymptomatic. They are more frequently observed at laparotomy and autopsy (1).

Although, hemangioma is the most frequent benign tumour of the liver, large symptomatic hemangiomas, so-called 'giant' hemangiomas are rare (2). In this paper, a case of 'giant' hemangioma of the liver encountered in a Samoan woman, is presented. Clinical, pathological features and treatment modalities were briefly discussed with the guidance of the literature.

CASE REPORT

A 43 year old Polynesian woman from the island nation of Western Samoa in the South Pacific was admitted to the Western Samoa National Hospital in the capital town, Apia on October 2, 1986. Her chief complaint was a feeling of mass in the right upper quadrant of the abdomen for a year. No associated symptoms regarding the mass were noted. She previously had 10 deliveries and 1 miscarriage. Clinically, it was first thought to be an ovarian cyst. Later on, a tumor adjacent to the left hepatic lobe was considered.

*: Pathologist, National Hospital, Apia, Western Samoa Islands, South Pacific (Present correspondence address: Assistant Professor, Department of Pathology, School of Medicine, Antalya).

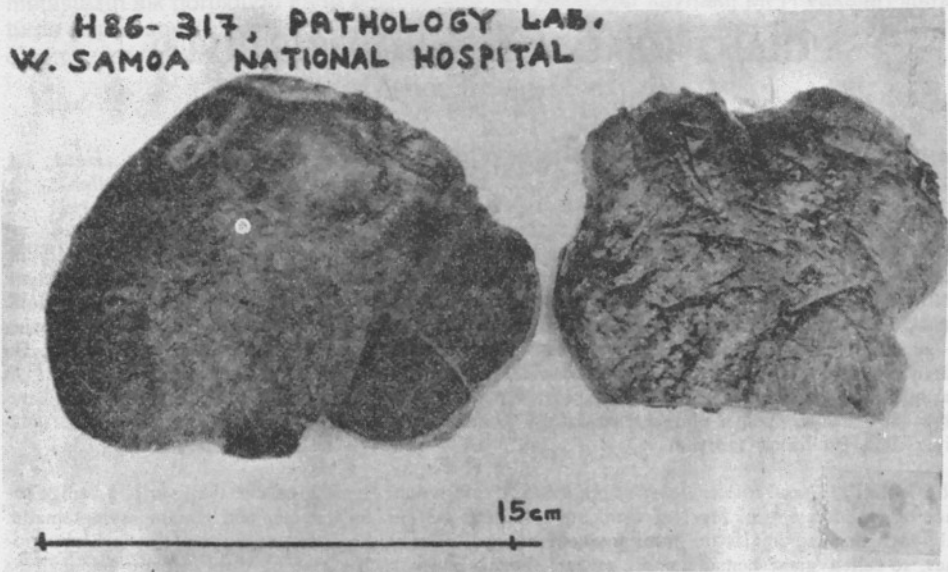


FIGURE 1: Gross and cross section appearance of our case of 'giant' hepatic hemangioma.

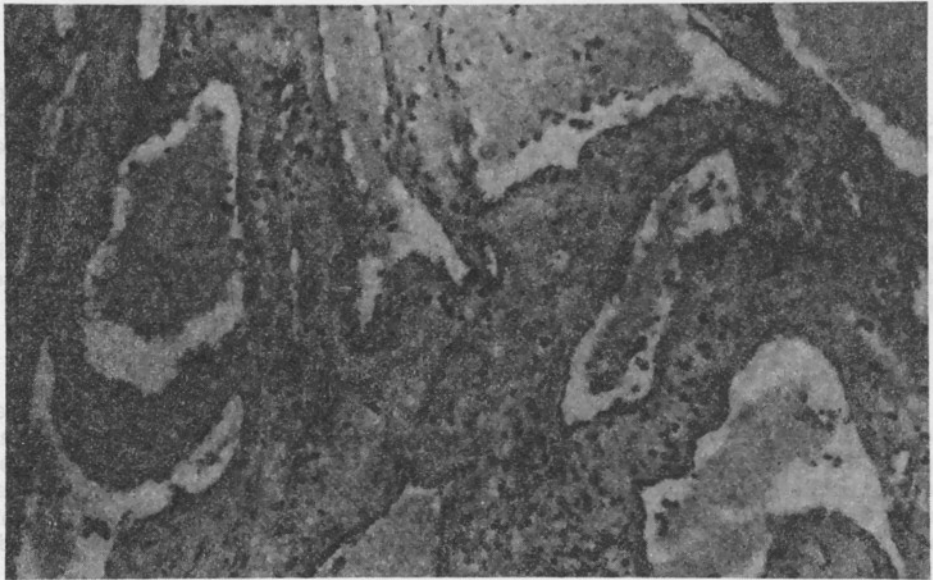

FIGURE 2: Microscopic appearance of cavernous hemangioma of the liver: markedly dilated, irregularly outlined, mostly blood-filled channels lined by flattened endothelial cells and fibrous connective tissue septa dividing the channels (HE, x 310).

Finally explorative laparotomy was applied and resection of the tumor including the neighbouring liver tissue was done due to the clinical diagnosis of 'hepatic tumor'. The postoperative course of the patient was uneventful and she was discharged 10 days later. There was no sign of recurrence during a two year follow-up period.

PATHOLOGICAL FEATURES

Macroscopically, the surgical specimen (reg. no: H86-317) was a solid, dark brown tumor measuring 15 x 13 x 5 cm. adjacent to the left hepatic lobe. On cross section, the tumor showed a homogenous dark purple appearance with a honeycomb pattern (Figure 1).

Microscopically, it was of 'cavernous hemangioma of the liver' with large, irregularly outlined, mostly blood-filled channels lined by flattened endothelial cells. These channels were divided by fibrous connective septa. Smooth muscle was seen in some of the vascular septa (Figure 2). Some areas also showed organising thrombus within the cavernous spaces. The adjacent liver tissue showed nodularity, some steatosis, and an infiltrate of polymorphs in the septa and capsule ('surgical hepatitis'). The lesion was demarcated from the liver, but not encapsulated (Figure 3).

DISCUSSION

Hemangiomas of the liver are usually ascribed to developmental anomalies, but the condition may also acquired as a result of localized necrosis and destruction of hepatic cells (1).

Because hepatic hemangiomas are usually small, averaging from 1 cm. to 2 cm. in diameter and also remain silent, most are discovered incidentally at laparotomy and autop-

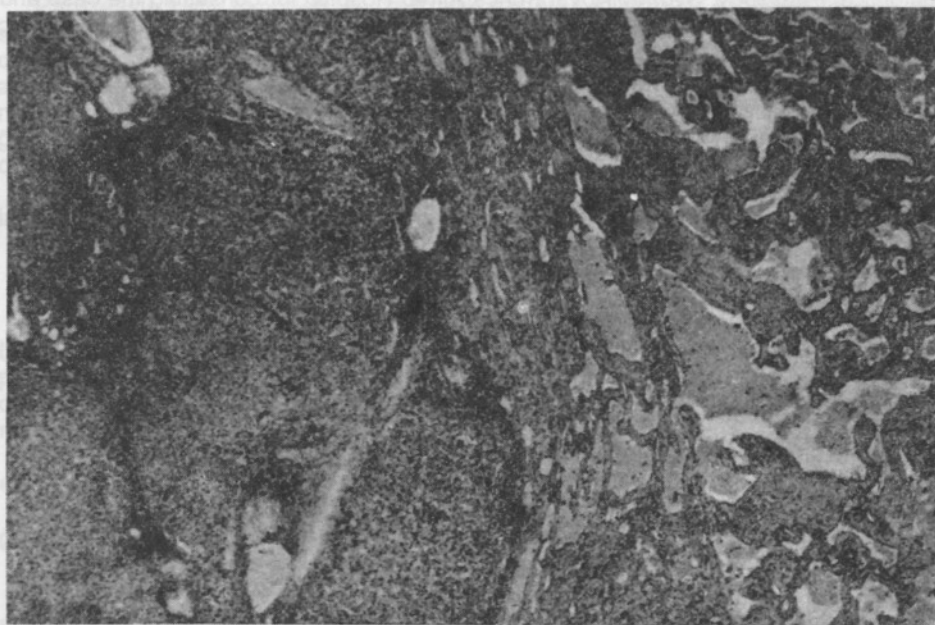

FIGURE 3: *The adjacent liver tissue showing nodularity and features of 'surgical hepatitis' (HE, x 32).*

sy. Various autopsy studies showed that the occurrence of cavernous hemangioma is not uncommon. Frequency varied between 2 and 7.3 % in autopsy series (3, 4). On the other hand, large symptomatic hemangiomas, so-called 'giant' hemangiomas are rarely seen. Adam et al. studied 22 patients with such 'giant' hemangiomas of the liver ranging from 6 cm. to 45 cm. in diameter seen during the years 1935 through 1965 at the Memorial Hospital for Cancer, New York City (2). In only 6 (27 %) out of these 22 cases, the diameter of the tumor was larger than 15 cm., which was the size of our case.

According to the literature, symptoms were directly related to the size of the tumor and pressure on adjacent organs, and these symptoms were non-specific (2). As happened in our case, frequently an abdominal mass is detected by the patient. The correct diagnosis seldom was made before operation and histopathological examination, but combined use of laparoscopy and hepatic arteriography recently increased the chance of preoperative diagnosis (2, 6). These facilities were not applied in our case, because they were unavailable at our hospital.

'Giant' hemangiomas may confine to either lobe or both hepatic lobes may be involved. There are two main treatment modalities reported: surgical resection or radiation therapy. Adam et al. suggest that, for symptomatic 'giant' hemangiomas confined to one lobe, the treatment of choice is resection. Large hemangiomas embedded in liver substance or replacing a hepatic lobe, can be treated by hepatic lobectomy. The alternative treatment for the diffuse cases where both liver lobes were involved, is radiation therapy (2). Arrest of growth and relief of symptoms are expected from the radiation therapy, not disappearance of the tumor. It is also pointed out that aspiration or biopsy of these vascular tumors is hazardous and might cause uncontrollable bleeding (4).

ACKNOWLEDGEMENTS

The author is grateful to Drs D. M. Painter and S. McCarthy from the Department of Anatomical Pathology, Sydney Royal Prince Alfred Hospital for consulting the case and providing the photomicrographs; to Dr P. J. Karhunen from the Department of Forensic Medicine, University of Helsinki for supplying the reference material.

REFERENCES

1. KARHUNEN P. J. Benign hepatic tumours and tumour like conditions in men. J Clin Pathol. 39: 183-88, (1986).
2. ADAM Y. G., HUVOS A. G., FORTNER J. G. Giant hemangiomas of the liver. Ann. Surg. 172: 239-45, (1970).
3. KARHUNEN P. J. Benign Tumors, Tumor-Like Conditions and Preneoplastic Lesions of the Adult Human Liver. (Academic Dissertation). Department of Forensic Medicine, University of Helsinki, Helsinki, Finland, (1986).
4. OCHSNER J. L. & HALPERT B. Cavernous hemangioma of the liver. Surgery 43: 577-82, (1958).
5. FELDMAN M. Hemangioma of the liver. Am J Clin Pathol 29: 160-62, (1958).
6. KATO M., SUGAWARA I., OKADA A., et al. Hemangioma of the liver. Diagnosis with combined use of laparoscopy and hepatic arteriography. Am J Surg 129: 698-704, (1975).