

## Tubulo-villous adenoma of the vagina — case report

Umit Cobanoglu, Yavuz Ozoran

Department of Pathology, Faculty of Medicine, Karadeniz Technical University, Trabzon, Turkey

Accepted for publication on 14 April 2004

**Background:** This report presents a case of tubulo-villous adenoma in the vagina of a 39 old woman, which is considered as a rare case.

**Case:** Gross examination revealed a polypoid tumor measuring 19x13x9 mm. Histologically cells lining the neoplastic tubulovillous glands were columnar with ovoid nuclei, and often stratified. Considerable amount of goblet cells were stained positive with HID/AB indicating the presence of sialomucin, which is considered to be colonic-like mucus.

**Conclusion:** This case is considered worthy to be reported, in order to emphasize the possible origin of this rare condition and the need for careful follow-up.

**Keywords:** tubulo-villous adenoma, intestinal metaplasia, female genital tract

### Introduction

Enteric tumors arising outside the gastrointestinal tract often cause diagnostic problems. Tubulo-villous adenomas of the vagina are extremely rare.<sup>1</sup>

### Case report

A 39-year-old woman suffered from vaginal discharge and contact bleeding for two months.

At gynecologic examination a polypoid tumor was found at the left lateral wall of the vagina. Cervical smears were normal. Rectosigmoidoscopic examination and barium enema revealed no further lesions. The tumor was resected totally.

Gross examination revealed a polypoid tumor measuring 19x13x9 mm. The cut surface was grayish-brown.

Histologically, cells lining the neoplastic tubulovillous glands were columnar with ovoid nuclei and often stratified. Considerable amount of goblet cells were seen (Figure 1, 2). The slides were stained with HID/AB. The goblet cells were stained positive indicating the presence of sialomucin, which is considered to be colonic-like mucus (Figure 3).

### Discussion

Tubulo-villous adenomas are well known neoplasms of the gastrointestinal tract; but other locations are rare. A few cases of enteric - like villous adenoma of the urethra and urinary bladder has been reported.<sup>1-3</sup> Enteric tumors of the female genital tract are extremely rare. Few cases of tubulo-villous adenoma of the vagina have been reported.<sup>4,5</sup> In

addition, tubulo-villous adenoma of the vulva, rectovaginal tract and enteric adenocarcinoma of the vagina have been also reported.<sup>5-8</sup>

Neither etiology nor predisposing factors in cases of enteric tumor in the female genital tract are known; but the possible mechanisms are:

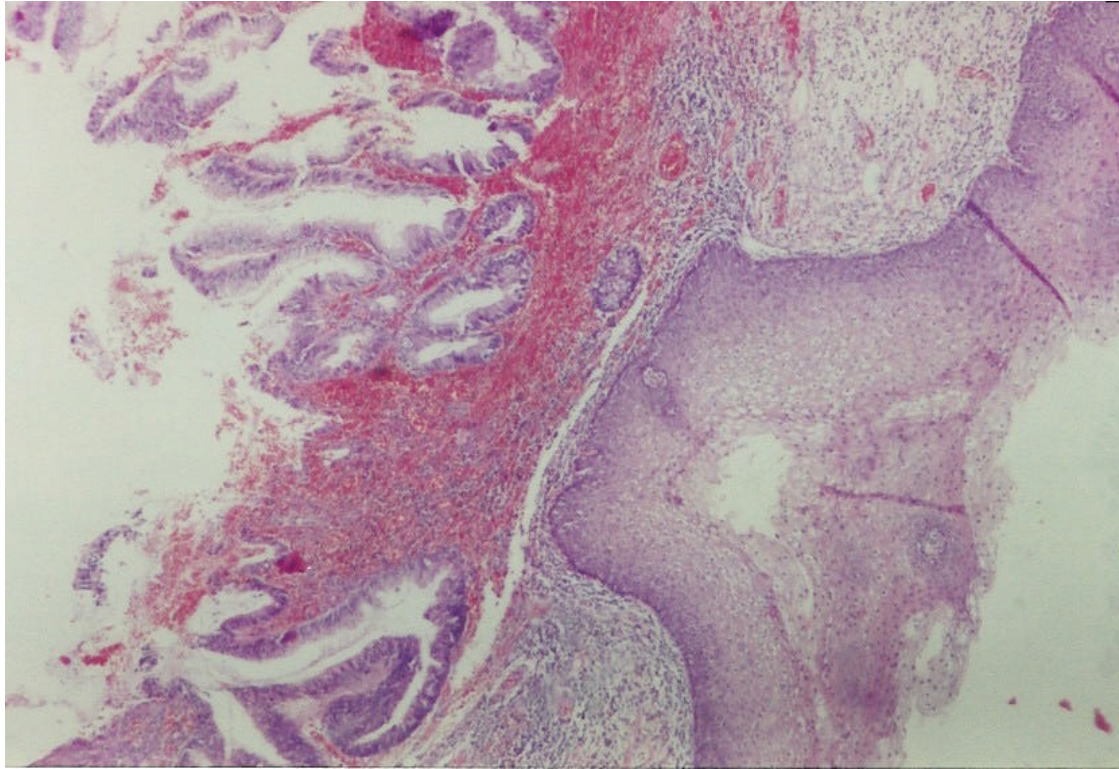
- 1) 'Congenital' ectopic intestinal epithelium of the genital tract as a result of embryological remnants,
- 2) 'Acquired' intestinal metaplasia followed by dysplastic changes of the epithelium,
- 3) Direct outgrowth from a gastrointestinal tumor,
- 4) Distant metastatic lesions from a gastrointestinal tumor.<sup>4</sup>

For, our patient, direct outgrowth from an intestinal tumor was ruled out, since rectosigmoidoscopic examination and barium enema of the colon was normal. Furthermore, no malignant histologic feature of the vaginal tumor was identified and therefore a metastatic lesion from a gastrointestinal tumor could be excluded.

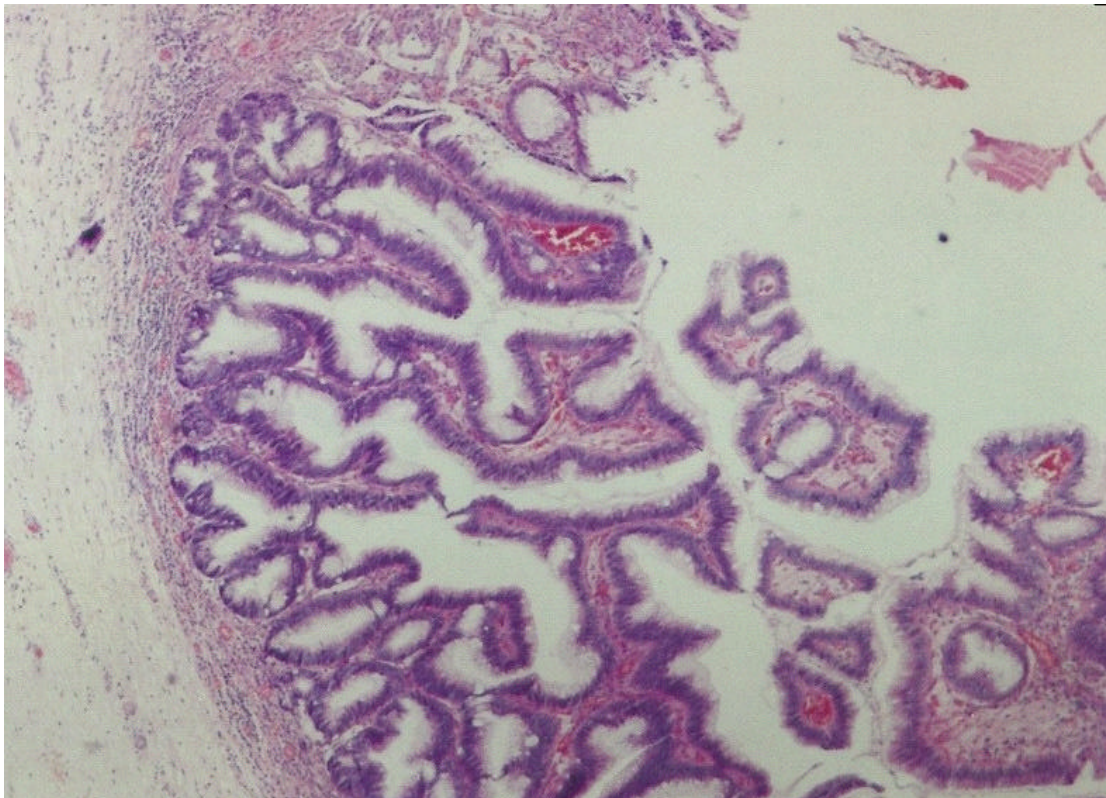
Intestinal metaplasia has been described in the urinary tract and in one case enteric adenocarcinoma was found.<sup>9</sup> Intestinal metaplasia of the cervix was described in three cases and in one of these three cases adenocarcinoma was present coincidentally.<sup>4</sup> It suggests that intestinal metaplasia can develop from tissue of Mullerian origin. The definitive vagina is derived from the urogenital sinus and it is probable that enteric tumors in this site arise from cloacal remnants.<sup>10</sup>

According to histological and mucin-histochemical examinations, the vaginal tumor was composed of the same type of epithelium found in adenomas of colon. This is supported by a case of tubulo-villous adenoma of the uterine cervix associated with invasive adenocarcinoma.<sup>12</sup> This

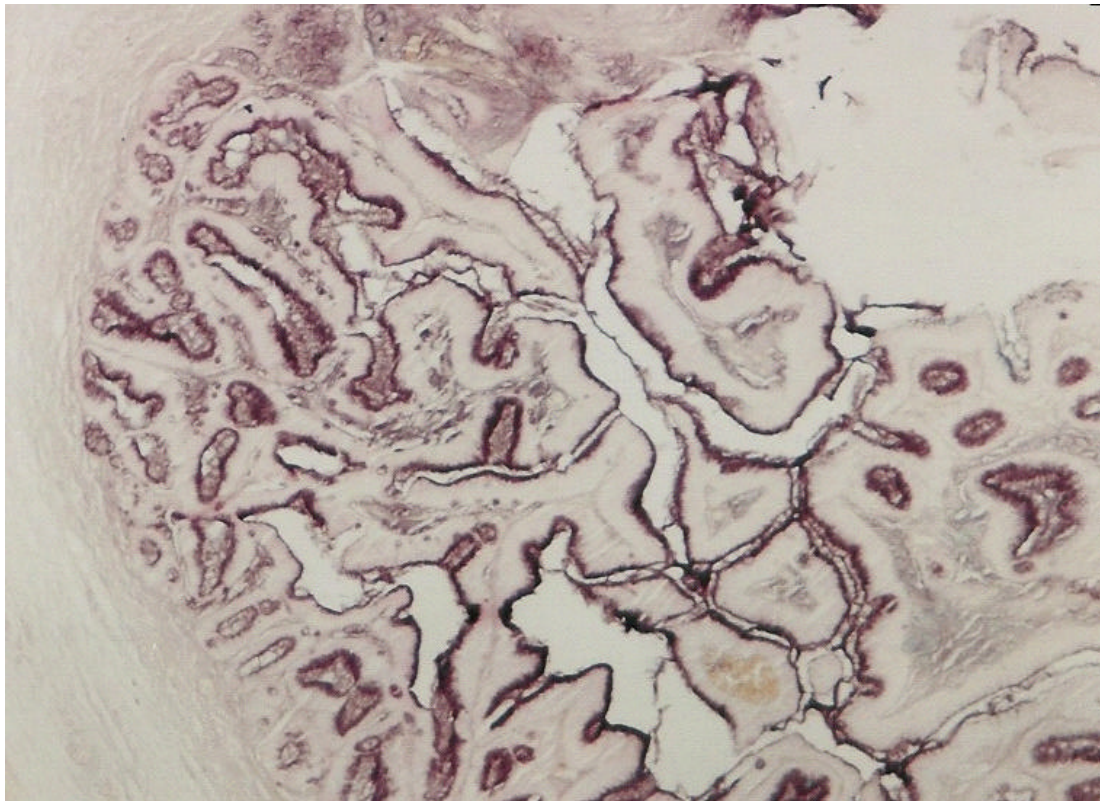
indicates that long term follow-up of patients with enteric tumors outside the gastrointestinal tract is advisable.<sup>5,13-14</sup>



**Figure 1.** Tubulo-villous adenoma is seen under the squamous epithelium of the vagina (Hematoxylin and eosin; x 40).



**Figure 2.** High power view of intestinal type tubulo-villous adenoma (Hematoxylin and eosin; x100).



**Figure 3.** HID/AB stain demonstrating positivity within colonic type epithelium of the adenoma (HID/AB; x 40).

## References

1. Assor D. A villous tumor of the bladder. *J Urol* 1978; 119: 287-288.
2. Powell I, Cartwright H, Jano F. Villous adenoma and adenocarcinoma of female urethra. *Urology* 1981; 18: 612-614.
3. Miller DC, Gang DL, Gavris V, Alroy J, Ucci AA, Parkhurst EC. Villous adenoma of the urinary bladder: a morphologic or biologic entity? *Am J Clin Pathol* 1983; 79: 728-731.
4. Mortensen BB, Nielson K. Tubulovillous adenoma of the female genital tract: A case report and review of literature. *Acta Obstet Gynecol Scand* 1991; 70: 161-163.
5. Fox H, Wells M, Harris M, McWilliam LJ, Anderson GS. Enteric tumors of the lower genital tract: a report of three cases. *Histopathology* 1988; 12:167-176.
6. Tiltman AJ, Knutzen VK. Primary adenocarcinoma of the vulva originating in misplaced cloacal tissue. *Obstet Gynecol* 1978; 51(Suppl 1): 30-33.
7. Ciano PS, Antonioli DA, Critchlow J, Burke L, Goldman H. Villous adenoma presenting as a vaginal polyp in a rectovaginal tract. *Hum Pathol* 1987; 18: 863-866.
8. Willen R, Bekassy Z, Carlen B, Bozoky B, Cajender S. Cloacogenic adenocarcinoma of the vulva. *Gynecol Oncol* 1999; 74: 298-301.
9. Gordon A. Intestinal metaplasia of the urinary tract epithelium. *J Pathol Bacteriol* 1963; 85: 441-444.
10. McLean JM. Embryology and anatomy of the female genital tract and ovaries. In Fox H (ed): *Haines and Taylor's Textbook of Obstetrical and Gynaecological Pathology*, Edinburgh, Churchill Livingstone, 1987, pp. 1-63.
11. Trowell JE. Intestinal metaplasia with argentaffin cells in the uterine cervix. *Histopathol* 1985; 9: 551-559.
12. Wells M, Tiltman A. Intestinal metaplasia of the endometrium. *Histopathol* 1989; 15: 431-433.
13. Micheal H, Sutton G, Hull MT, Roth LM. Villous adenoma of the uterine cervix associated with invasive adenocarcinoma: a histologic, ultrastructural, and immunohistochemical study. *Int J Gynecol Pathol* 1986; 5: 163-167.
14. Azzopardi JG, Hou LT. Intestinal metaplasia with argentaffin cells in cervical adenocarcinoma. *J Pathol Bacteriol* 1965; 90: 686-690.