

## A case of adenomyosis in an overweighting uterus\*

Metin Akbulut, Çiğdem Berna Ege, Ferda Bir

Department of Pathology, Faculty of Medicine, Pamukkale University, Denizli, Turkey

Accepted for publication on 2 August 2005

\*This case was presented as a poster at XXIII. World Congress of Pathology and Laboratory Medicine, 26–60 May 2005, Istanbul, Turkey

**Background:** Adenomyosis can not be usually diagnosed accurately and differentiated from leiomyoma before histological examination in a hysterectomy material.

**Case:** A 37-year-old woman underwent abdominal hysterectomy and unilateral salpingo-oophorectomy for menorrhagia with an initial clinical diagnosis of multiple intramural leiomyomas. Histological examination showed foci of adenomyosis in the myometrium. The specimen was 400 g in weight. No leiomyomatous nodule was detected on the serial sections of the myometrium.

**Conclusion:** This case appears to be a nice example of how adenomyosis can cause significant enlargement of the uterus and may be misdiagnosed as leiomyomatosis.

**Keywords:** adenomyosis, uterine size

### Introduction

Adenomyosis refers to the presence of islands of endometrial glands and stroma within the myometrium.<sup>1</sup> When adenomyosis is focal, it mimics a leiomyoma in being a roughly spherical, intramural, space-occupying lesion, but it differs from leiomyoma since the mass cannot be shelled out easily from the uninvolved myometrium.<sup>2</sup> So adenomyosis, can not be usually diagnosed accurately and differentiated from leiomyoma before the pathological examination of the uterus.

### Case report

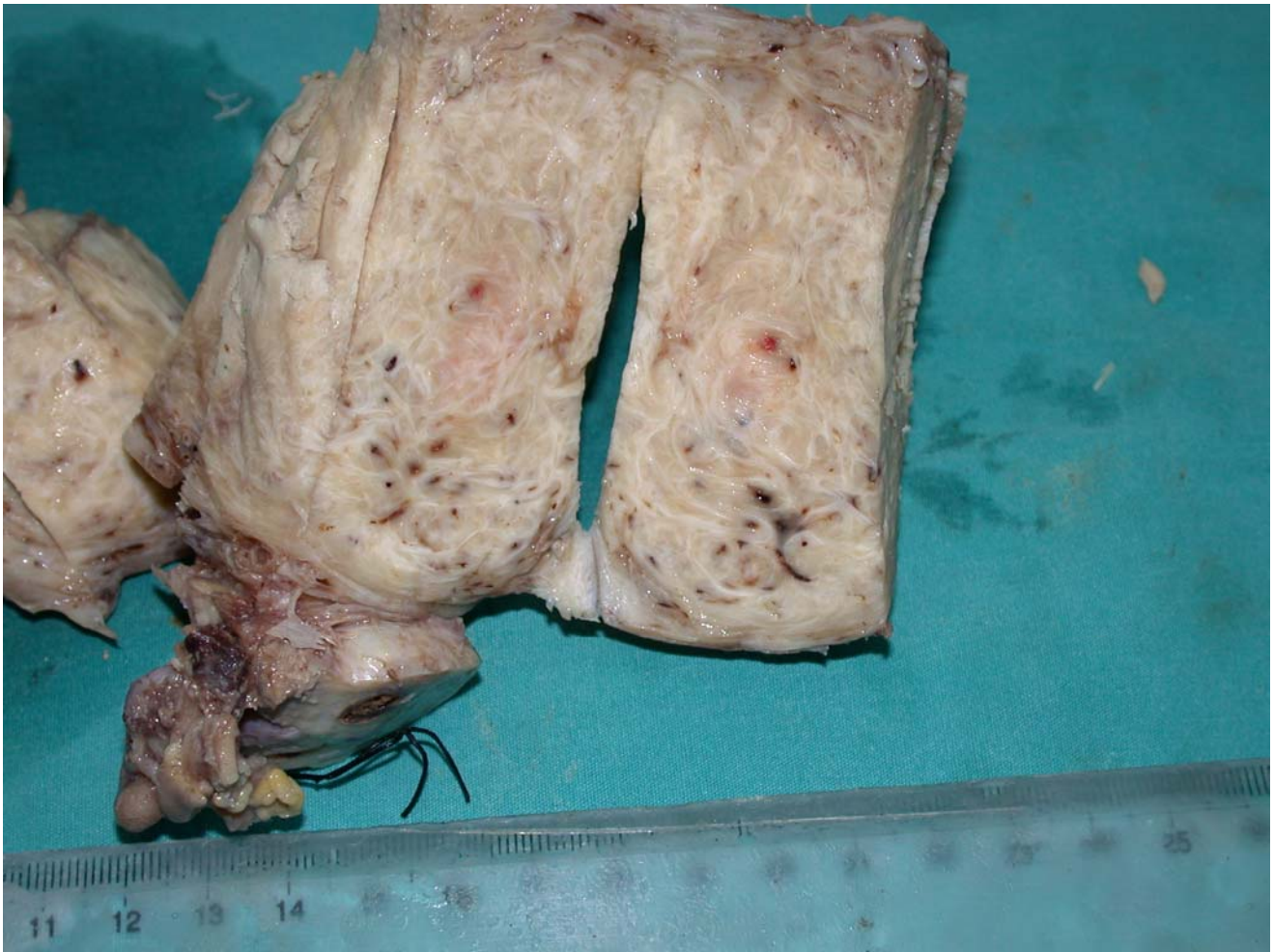
A 37-year-old premenopausal woman, gravida 4, para 2 was referred for surgical management of left ovarian cyst unresponsive to hormonal therapy and menorrhagia due to clinical diagnosis of uterine leiomyomata. She had no chronic illness and medication. She underwent a procedure including abdominal hysterectomy and unilateral salpingo-oophorectomy. On to the pathologic evaluation, the

only abnormality in the uterus with a weight of 400 g was diffuse adenomyosis. The cut surface of the myometrium consisted of multiple red to pink trabecular appearing areas (Figure 1). No distinct tumor masses were identified.

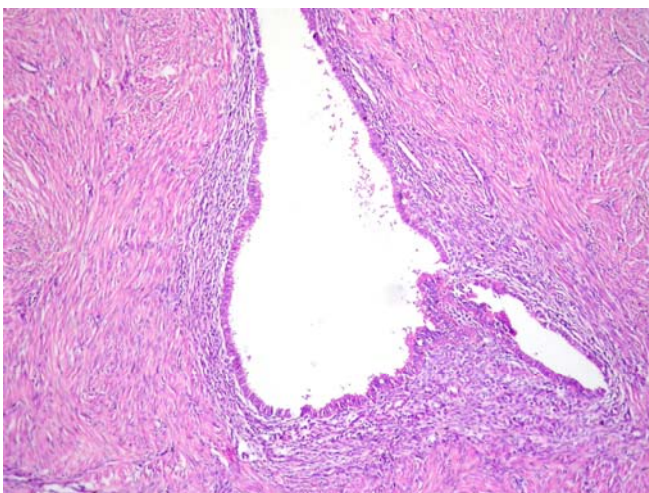
Microscopically, multiple irregular islands of endometrial glands and stroma were embedded diffusely in the myometrium and the entire uterine wall (Figure 2). The myometrium surrounding the infiltrating endometrium was hypertrophic. The glands in the endometrial islands were of basalis-type in contrast to the early-secretory glands in the endometrium. The left ovary consisted of a follicle cyst.

### Conclusion

Generally, adenomyosis does not cause gross abnormality and the diagnosis is based entirely upon microscopic findings. When organ involvement is diffuse like in this case, the uterus is enlarged in a globoid fashion.



**Figure 1.** Macroscopic appearance of the uterine wall with trabecular pattern.



**Figure 2.** Benign endometrial glands and stroma are embedded in the myometrium (H&E; x10)

In Lev Gur's series<sup>3</sup>, adenomyosis was present alone only in the uteri smaller than 280 g. Reiter et al. reported six women with an average uterine weight of 320 g without reporting the maximum weight in their

series.<sup>4</sup> We also encountered another case of overweighing uterus (475 g) with isolated adenomyosis reported in the literature.<sup>5</sup>

A clinical diagnosis of adenomyosis can often be confirmed by imaging studies such as transvaginal ultrasonography and MRI, but specificity of these methods decreases when the uterine volume exceeds 400 ml.<sup>6</sup> Taken together, this case is a nice example of how adenomyosis can cause significant enlargement of the uterus and may be misdiagnosed as leiomyomatosis preoperatively.

## References

1. Rosai J. Female reproductive system. In: Ackerman's Surgical Pathology, 8th ed., Mosby, St. Louis, 1996; 1401–1403.
2. Sternberg S.S. The uterine corpus. In: Diagnostic Surgical Pathology, 3rd ed., Lippincott Williams&Wilkins, 1999; 2271.
3. Lev Gur M. The enlarged uterus; Relation of the uterine size to symptoms and histopathologic findings. *J Reprod Med* 1996; 41; 166–170.

4. Reiter RC, Wagner PL, Gambone JC. Routine hysterectomy for large asymptomatic uterine fibroids; A reappraisal. *Obstet Gynecol* 1992; 79; 481-484.
5. Harmanlı OH, Shen T, Zhu S, Chatwani AJ. A case of adenomyosis per se with an uterine weight of 475 g. *Gynecol Obstet Invest* 2004; 58; 216–218.
6. Dueholm M, Lundorf E, Hansen ES, Sorensen JS, Ledertoug S, Olesen F. Magnetic resonance imaging and transvaginal ultrasonography for the diagnosis of adenomyosis. *Fertil Steril* 2001; 76, 588–594.