

Intramuscular lipoma of the tongue: A case report and review of the literature

Metin Akbulut, Ayşegül Aksoy, Ferda Bir

Department of Pathology, Faculty of Medicine, Pamukkale University, Denizli, Turkey

Accepted for publication on 12 September 2005

*This case was presented as a poster at XXIII. World Congress of Pathology and Laboratory Medicine, 26–60 May 2005, Istanbul, Turkey

Purpose: Although lipomas are the most common neoplasms of the soft tissue; they are only presenting 1 to 5 percent of all of the benign neoplasms of the oral cavity. Oral lipomas affect predominantly the buccal mucosa, floor of mouth, tongue and lips. Intramuscular (infiltrating) lipoma of the tongue is an extremely rare variant of lipoma and a few cases have been reported until now.

Case: A 50-year-old woman, who had exophytic, painless lesion on the right lateral border of the tongue, has gone to surgery for excision. Macroscopically, the mass was polypoid, had a soft consistency and measured 0.6x0.5x0.2 cm. Microscopic examination of the haematoxylin-eosin stained sections showed intact squamous epithelium over the surface. The submucosa revealed adipocytes, which lie down through the skeletal muscle fibers and extend to the epithelial level.

Conclusion: When a painless, slow growing, well demarcated lesion occur on the tongue, although it is uncommon, one must remember intramuscular lipomas. Although until now a few cases have been reported, with the same histological and clinical appearance, well-differentiated liposarcoma must be excluded and surgical excision should be carefully done.

Keywords: Lipoma, intramuscular, tongue

Introduction

Lipomas are common, benign tumors located in any part of the body in which fat is normally present.^{1,2} Although lipoma is the most common of all connective tissue lesions, it is unusual in the tongue. Lipomas have different subtypes, such as angiolipoma, intramuscular (infiltrating) lipoma, benign lipoblastoma, spindle cell lipoma and pleomorphic lipoma, but 80% of them are ordinary lipomas.¹ Intramuscular lipoma is usually found in the muscles of the extremities, but it is exceedingly rare in the tongue. To our knowledge there are only a few cases reported in the literature^{2–13} (Table 1).

We present an intramuscular lipoma of the tongue in a 50-year-old woman and also review the international literature concerning about the clinical

presentation, microscopical characteristics, differential diagnosis and treatment.

Case report

A 50-year-old woman presented with a history of a small exophytic, painless lesion on her tongue which first appeared 3 months ago and enlarged gradually. It did not interfere with her airway, oral intake, or speech. There were no cervical masses or salivary gland alterations. Examination revealed non-tender, well demarcated mass protruding from the right lateral border of the tongue. Excisional biopsy of the tumor was performed under local anesthesia. At gross examination, specimen was polypoid, had a soft consistency and measured 0.6x0.5x0.2 cm. It was promptly fixed in formalin, embedded in paraffin and

Table 1. Clinicopathological features of intramuscular lipoma of the tongue.

No	Authors	No of cases	Gender	Age (yr)	Max diameter (cm)	Subtype
1	Bernhoff and Wood 1978	1	M	68	NA	
2	Brahney 1981	1	F	81	NA	
3	Gouillou 1986	1	F	60	NA	Pleomorphic
4	Garavaglia and Gnepp 1987	1	M	38	1,5	
5	Shirasuna 1989	1	F	56	1,8	
6	Takeda 1989	1	M	37	1,4	
7	Lombardi and Odell 1994	1	F	68	NA	Spindle cell
8	Kacker 1996	1	M	79	6	Atypical lipomatous
9	Karapantzos 1998	1	F	77	3	
10	Epivatianos 2000	2	F-F	56–64	3–2,5	
11	Keskin 2002	1	M	54	1	Multiple
12	Fregnani 2003	2	NA	NA	NA	
13	Furlong 2004	8	NA	NA	NA	
14	Present case 2005	1	F	50	0,6	

NA: Not available

stained with haematoxylin-eosin. On sectioning, the mass was found to be unencapsulated. Microscopic examination showed an intact but thinned stratified squamous epithelium covering the surface (Figure 1). The submucosa revealed mature adipocytes extending to the epithelial level and which lie down through the irregular bundles of skeletal muscle fibers (Figure 2). Some of the entrapped muscle fibers exhibited varying degrees of atrophy. No cellular atypia, necrosis, mitotic activity, vascularization and lipoblastic proliferation was observed. The patient had no perioperative problems and is without evidence of recurrence at a 60-month follow-up period.

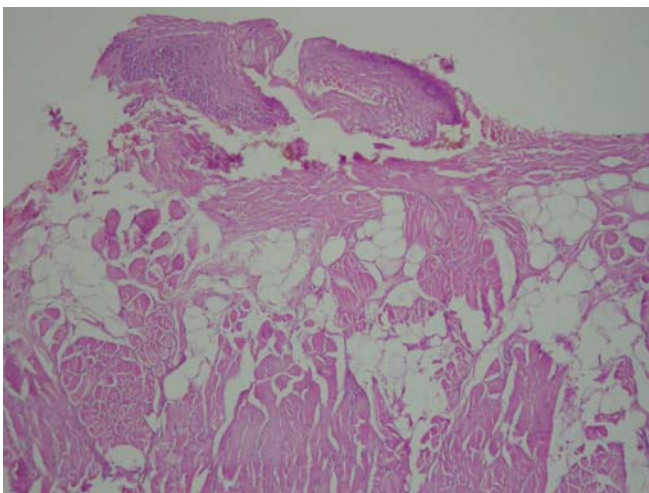


Figure 1. A more prominent network of small vessels surrounded by stromal cells in endometrial stromal nodule (HE; x50)

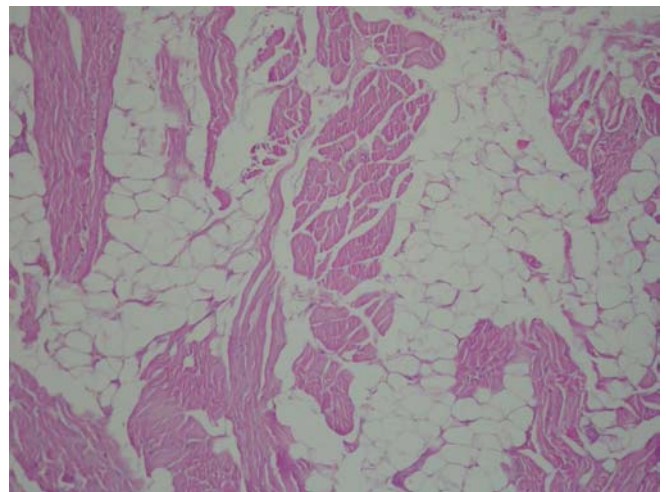


Figure 2. Adipocytes through the muscle fibers (H&E, x20)

Discussion

Lipomas are very frequent tumors in the human body, but their appearance in the oral cavity is exceptional,² being no more of 4 % of the tumors in this region in different studies.^{1-3,15} Lipomas have different subtypes, such as angiolipoma, intramuscular lipoma, benign lipoblastoma, spindle cell lipoma and pleomorphic lipoma, but 80 % of them are ordinary lipomas.¹ Intramuscular lipoma is usually well defined, but has no capsule and infiltrates into skeletal muscle. Extremities are the sites of greater incidence of this mesenchymal tumor.

To summarize the clinical situation, diagnosis, and treatment experience of intramuscular lipoma of the tongue, we have reviewed the current literature and found isolated cases with intramuscular lipoma of the tongue.

Among the available 13 cases reported in the literature, 5 lipomas occurred in males, 8 in females. The age ranged from 37 to 81 years with a mean age of 60,6 years. The size of tumors was ranged 0,6 to 6 cm. Most patients presented with an asymptomatic, circumscribed mass. Recently Fregnani et al and Furlong et al reviewed the oral cavity lipomas and reported 8 and 2 patients with intramuscular lipoma respectively. But they did not give any information about the age and gender of the patients in their reports.^{2,3}

Oral lipomas affect predominantly the buccal mucosa, floor of mouth, tongue and lips.^{2,3} Oral cavity lipomas show a slow painless and asymptomatic growing and appear in the fourth and fifth decade without sexual predilection.⁴ However, lipomas are often seen in males when they are located in the tongue. They are usually located immediately beneath the mucosa and seen at the organ's lateral edge and in the anterior two-thirds. Although most of the lesions reported in the literature were solitary, one patient had multiple intramuscular lipomas located in the right and left lateral border of the tongue.⁶

Preoperative imaging studies should be performed to aid in surgical planning. If there is a question that the mass extends into the deep tongue musculature, preoperative imaging can define the depth of the mass in relation to the normal tongue tissue.

Intramuscular lipomas are of primary importance because of their differential diagnosis with liposarcomas due to its large size, deep location and their ability to infiltrate adjacent muscles and recur locally. Therefore, detailed histological examination is essential in all intramuscular lipomas, which can be commonly misdiagnosed as liposarcoma. Differential diagnostic criteria were summarized in Table 2. The intramuscular lipoma is usually well demarcated, but has no capsule and infiltrates into the adjacent muscle. Our case had no areas of lipoblastic proliferation, nuclear atypia and mitosis. Other entities should also

be considered in the differential diagnosis of intramuscular lipoma, these include spindle cell lipoma, myxoma, myxosarcoma, benign fat tumours (hibernoma), fibrolipoma, angiolipoma, schwannomas, cysts, lingual thyroids, adenomas of the minor salivary glands, granular cell myoblastomas, and angiomas.⁹⁻¹¹

Surgical excision is the mainstay of treatment for these lesions. Approach to resection is based on accessibility to the mass, size of the mass, and concern for postoperative airway obstruction secondary to lingual swelling. The recurrence rate for infiltrating lipomas has been reported to be 3 to 62,5 per cent.^{8,10} They have propensity to recur without adequate surgery, therefore complete surgical excision is mandatory. Long-term follow up was recommended and so far, after 60 months, our patient is free of disease.

Table 2. Differential diagnostic criteria of intramuscular lipoma with well-differentiated liposarcoma.

	Intramuscular (infiltrating) Lipoma	Well-differentiated liposarcoma
Lipoblast	No	Yes
Myxoid differentiation	No	Yes
Cellular pleomorphism	Rarely	Usually
Increased vascularity	Minimal, Capillary	Abundant
Mitosis	No	Yes

When a painless, slow growing, well demarcated lesion occur on the tongue, although it is uncommon, one must remember intramuscular lipomas. Although until now a few cases have been reported, with the same histologic and clinical appearance, well-differentiated liposarcoma must be excluded and surgical excision should be carefully done.

References

1. Fletcher CDM, Unni KK, Mertens F. Adipocytic tumors. In: Pathology and genetics: tumours of soft tissue and bone. World Health Organization classification of tumours. Lyon, France: IARC Press; 2002. pp 9-46.
2. Fregnani ER, Pires FR, Falzoni R, Lopes MA, Vargas PA. Lipomas of the oral cavity: clinical findings, histological classification and proliferative activity of 46 cases. *Int J Oral Maxillofac Surg* 32 (1): 49-53, 2003.

3. Furlong MA, Fanburg-Smith JC, Childers EL. Lipoma of the oral and maxillofacial region: Site and subclassification of 125 cases. *Oral Surg Oral Med Oral Pathol Oral Radiol Endod* 98(4): 441-50, 2004.
4. Epivatianos A, Markopoulos AK, Papanayotou P. Benign tumors of adipose tissue of the oral cavity: a clinicopathologic study of 13 cases. *J Oral Maxillofac Surg* 58(10): 1113-18, 2000.
5. Bennhoff DF, Wood JW. Infiltrating lipomata of the head and neck. *Laryngoscope* 88(5): 839-48, 1978.
6. Keskin G, Ustundag E, Ercin C. Multiple infiltrating lipomas of the tongue. *J Laryngol Otol* 116(5): 395-7, 2002.
7. Guillou L, Dehon A, Charlin B, Madarnas P. Pleomorphic lipoma of the tongue: case report and literature review. *J Otolaryngol* 15(5): 313-6, 1986.
8. Garavaglia J, Gnepp DR. Intramuscular (infiltrating) lipoma of the tongue. *Oral Surg Oral Med Oral Pathol* 63(3): 348-50, 1987.
9. Takeda Y. Intramuscular lipoma of the tongue: report of a rare case. *Ann Dent* 48(2): 22-4, 1989.
10. Shirasuna K, Saka M, Watatani K, Kogo M, Matsuya T. Infiltrating lipoma of the tongue. *Int J Oral Maxillofac Surg* 18(2):68-9, 1989.
11. Kacker A, Taskin M. Atypical intramuscular lipoma of the tongue. *J Laryngol Otol* 110(2): 189-91, 1996.
12. Karapantzos I, Kehl R, Behrmann R, Markmann HU. Tongue tumor of uncertain origin. Intramuscular lipoma of the tongue. *HNO* 46(12): 998-9, 1998.
13. Lombardi T, Odell EW. Spindle cell lipoma of the oral cavity: report of a case. *J Oral Pathol Med* 23(5):237-9, 1994.
14. Brahney CP, Aria AA, Koval MH, Najjar TA. Angiolipoma of the tongue: report of case and review of literature. *J Oral Surg* 39(6):451-3, 1981.
15. Roles DM. Lipoma of the tongue. *Br J Oral Maxillofac Surg* 33: 196-7, 1995.