

The Role of CD56, HBME-1, and p63 in Follicular Neoplasms of the Thyroid

Tiroidin Folliküler Neoplazmlarında CD56, HBME-1 ve p63'ün Rolü

Hülya ETEM¹, Selver ÖZEKİNCİ², Bülent MIZRAK², Senem ŞENTÜRK³

Departments of Pathology, ¹Kızıltepe State Hospital, MARDİN, TURKEY, ²Dicle University, Faculty of Medicine and ³Radiology, Dicle University, Faculty of Medicine, DİYARBAKIR, TURKEY

The article has been presented as a poster at the 19th National Pathology Congress held in Girne, Turkish Republic of Northern Cyprus on October 7-11, 2009.

ABSTRACT

Objective: Carcinomas originating from thyroid follicular cells are the commonest of all endocrine system malignancies. In this study we evaluated the importance of the expressions of CD 56, HBME-1 and p63 in the differential diagnosis of the follicular variant of papillary carcinoma from other follicular neoplasms.

Material and Method: We re-evaluated 80 cases of thyroid neoplasms, comprising 40 cases of follicular variant of papillary thyroid carcinoma and 40 cases of follicular neoplasm, diagnosed at Dicle University Medical School, Department of Pathology between 2005 and 2008. All neoplasms were stained with CD 56, HBME-1 and p 63 compared to each other. Statistical analysis was with Student's t test and the Yates corrected chi-square test.

Result: There was no statistically significant difference in the expression of CD 56 between follicular neoplasms and papillary carcinomas, but HBME-1 and p63 expressions were statistically significantly different between these neoplasms (p=0.005, p=0.0001).

Conclusion: The use of HBME-1 and p63 may be helpful in differentiating papillary carcinoma, particularly follicular variant, from follicular neoplasms.

Key Words: Thyroid cancer, Papillary thyroid carcinoma, Follicular neoplasms

ÖZ

Amaç: Tiroidin follikül epitelinde gelişen karsinomları endokrin sistem kanserleri içinde en sık görülenidir. Çalışmamızda papiller tiroid karsinomu folliküler varyantının folliküler neoplazmlardan ayırıcı tanısında CD56, HBME-1 ve p63 ekspresyonunun katkısını araştırdık.

Gereç ve Yöntem: 2005-2008 yılları arasında Dicle Üniversitesi Tıp Fakültesi Patoloji Anabilim Dalı'nda tiroid papiller karsinomu folliküler varyantı tanısı alan 40 olgu ile 40 folliküler neoplazm olgusu retrospektif olarak incelendi. Folliküler tümörler ve papiller karsinomlar CD56, HBME-1 ve p63 ile boyanma özelliklerine göre karşılaştırıldı. İstatistiksel çalışmada Student'in t testi ve Yates düzeltilmiş ki-kare testi ile analiz yapıldı.

Bulgular: Folliküler neoplazmlar ile papiller karsinomlar arasında, CD56 ekspresyonu açısından istatistiksel olarak anlamlı fark izlenmedi; HBME-1 ve p63 ekspresyonu yönünden istatistiksel olarak anlamlı fark saptandı (p=0,005, p=0,0001).

Sonuç: HBME-1 ve p63'ün tiroid papiller karsinomlarının, özellikle de folliküler varyantın folliküler neoplazmlardan ayırımında katkısı olduğu düşünüldü.

Anahtar Sözcükler: Tiroid kanseri, Tiroid papiller karsinomu, Folliküler neoplazmlar

INTRODUCTION

Primary cancers of the thyroid make up 1-1.5% of primary malignant tumors. The most common endocrine system malignancies are carcinomas developing from follicular epithelium. Genetic, environmental and hormonal factors play a role in the pathogenesis of thyroid cancers (1). Specific nuclear structures in papillary thyroid cancer (PTC) and invasion in follicular cancer are diagnostic features. It is therefore not possible to differentiate thyroid nodules with imaging methods (2).

Thirteen PTC subtypes have been defined. The most common subtype is the follicular variant. Distant metastases such as to the lung and bones in addition to multicentricity, vascular invasion and nodal distribution are frequently encountered in follicular variant PTC (1,3).

Various immunohistochemical markers have been used in the differentiation of PTC and especially the follicular variant from other follicular tumors (4-7). We studied the CD56, p63, HBME-1 immunohistochemical markers to

Received : 15.10.2009

Accepted : 04.06.2010

Correspondence: Selver ÖZEKİNCİ

Department of Pathology, Dicle University, Faculty of Medicine, DİYARBAKIR, TURKEY

E-mail: drselver@gmail.com Phone: +90 505 293 49 43

determine their contribution to the differential diagnosis of PTC follicular variant with follicular tumors.

CD56 is a neural cell adhesion molecule and its migration influences the migratory characteristics of tumor cells. CD56 is present in the follicular epithelial cells of the normal thyroid (8). Various studies have reported that CD56 does not stain in PTC while staining is present in most follicular tumors (4,5,9).

The HBME-1 (Hector Battifora Mesothelial cell) antibody has been shown in mesothelial cells by Battifora et al. HBME-1 is the most specific (96%) marker known for malignant tumors derived from follicular epithelium (10-12). It is used in the differential diagnosis of PTC and papillary hyperplasia and has been shown to be quite specific (5).

p63, a member of the tumor suppressor gene family, is the homologous nuclear transcription factor of p53 and is essential for normal development (13-16). p63 plays a key role in epithelial proliferation and differentiation and causes defects in epithelial differentiation (16). Various studies have demonstrated that p63 is present in the basal layer of squamous epithelium, in breast and prostate myoepithelial cells and in the transitional epithelium of the bladder (16-18). Its tumor suppressor effects are quite controversial although it is from the p63 tumor suppressor gene family and mutations in these genes are quite rare in human malignancies. Focal staining is expected in PTC while some reports state no staining in other thyroid tumors (4,19,20).

MATERIAL and METHOD

A total of 40 cases diagnosed as follicular tumor (35 follicular adenoma, 3 follicular carcinoma and 2 tumors of undetermined malignant potential) and 40 cases diagnosed as PTC follicular variant at the Pathology Department of Dicle University Medical Faculty between 2005 and 2008 were included in two groups as our study. Sections 4 µm thick were obtained from the paraffin-embedded blocks of the cases. Staining was performed with the CD56, HBME-1 and p63 antibodies using the immunoperoxidase method. Both groups were evaluated separately and comparatively according to the expression with the three antibodies.

Immunohistochemical Method:

The sections that were 4 µm thick and obtained on positive charged slides from the paraffin block for the immunohistochemical study with CD56/NCAM-1, HBME-1 (Mesothelin), and p63 (Thermo Scientific, USA), antibodies were deparaffinized. Dehydration was performed in 96-degree ethyl alcohol and antigen recovery was carried

out in a microwave oven in pH 6.0 citrate buffer solution. The sections were cooled to 20 minutes at room temperature and kept in 10 minutes 0.3% hydrogen peroxide solution. PBS (phosphate buffer saline, PH 7.4) was used to wash the sections while the standard avidin-biotin complex (ABC) method was used as the immunohistochemical method. AEC (3-amino-9-ethylcarbazole) (Ultra Vision LP Value Detection System HRP Polymer&AEC Chromogen, Thermo Scientific, USA) was kept in the substrate solution for 10 minutes and washed with distilled water. Counterstaining was performed for 2 minutes with Mayer hematoxylin. The preparations were evaluated with an Olympus model CX21FS1 light microscope.

The positive controls used were pancreas for CD56, pleura for HBME-1, and skin tissue for p63.

Evaluation:

Cytoplasmic and membranous staining for CD56, basolateral membranous staining for HBME-1 and nuclear and cytoplasmic staining for p63 were accepted as positive in the tumor cells. For the three antibodies, >10% staining in the tumor was accepted as positive while a value <10% was negative.

Student's t test and Yates corrected Chi-Square test were used for statistical analysis.

RESULTS

CD56 staining was present in 14 follicular tumors (35%) and 14 PTC follicular variants (35.0%) (Figure 1). There was no staining in 26 (65,0%) cases in both groups. There was no statistically significant difference between follicular tumors and PTC for CD56 staining ($p=0.186$).

HBME-1 staining was present in 5 (12.5%) and absent in 35 (87.5%) follicular tumors. There was diffuse staining in 16 (40%) PTC cases (Figure 2) and no staining in 24 (60.0%). There was a statistically significant difference between follicular tumors and PTC for HBME-1 staining ($p=0.005$).

p63 staining was present in 3 (7.5%) follicular tumors (2 follicular adenomas, 1 follicular carcinoma) and absent in 37 (92.5%). Staining was present in 12 (30.5%) PTC cases (Figure 3) and absent in 28 (70%). There was a statistically significant difference between follicular tumors and PTC for p63 expression ($p=0/0001$). PTC cases were found to show a higher rate of staining with p63 than follicular tumors.

DISCUSSION

PTC cases are the most common carcinomas of the thyroid and although easily recognizable, they can be difficult

to diagnose, especially with the follicular variant. Some pathologists seem to disagree on this point (21). A study by eight American and Japanese pathologists showed a concordance of 62% in the benign and malignant differentiation of thyroid nodules while this rate was 53% regarding whether the lesions were neoplastic or not and 0% in the diagnosis of PTC and follicular carcinoma (22).

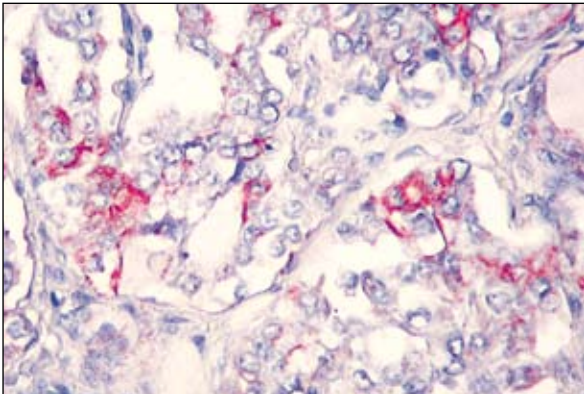


Figure 1: CD56 staining in papillary carcinoma (x400).

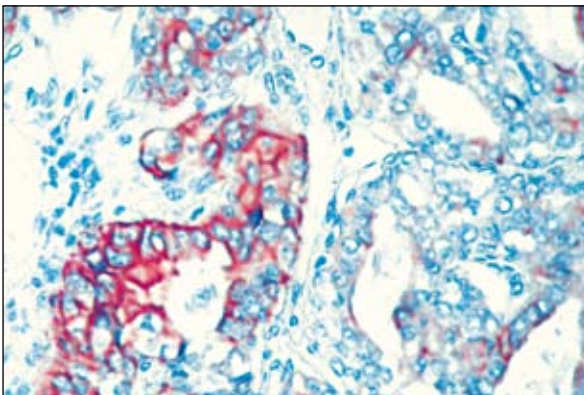


Figure 2: HBME-1 staining in papillary carcinoma (x400).

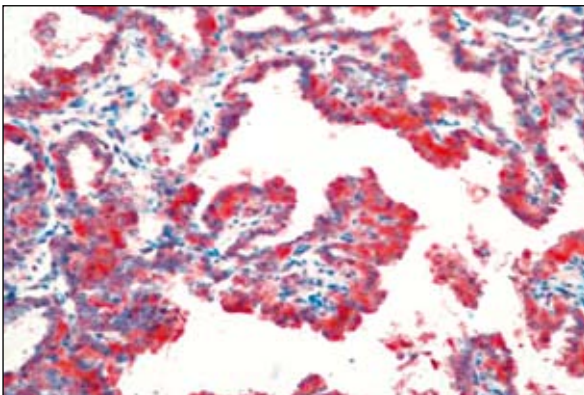


Figure 3: Nuclear and cytoplasmic p63 staining in papillary carcinoma (x200).

Although immunohistochemical and molecular methods are used in the diagnosis of tumors derived from the follicular epithelium of the thyroid, the gold standard is histopathological investigation. Immunohistochemical studies are helpful but there is no marker that can definitely differentiate PTC from other follicular thyroid lesions and is 100% consistent at present (4).

CD56 has been reported to be an antigen related to the differentiation of follicular epithelium (23). Normal thyroid tissue, benign thyroid disease and follicular tumors show membranous staining while staining in PTC is weak or absent (4,24). CD56 has also been reported to decrease tumor invasion by suppressing VEGF-D (25).

We found no CD56 staining in 35% of both follicular tumors and papillary carcinomas. There was no statistically significant difference between follicular tumors and PTC regarding CD56 staining. Our results are not consistent with literature data. This may be due to our small number of cases or tumor differentiation.

HBME-1 is reported to be a reliable marker in the diagnosis of PTC and the differentiation of PTC and papillary hyperplasia (5) with a specificity of 96% in PTC (26) while a rate of 100% has been given for HBME-1/CK19 coexpression (27). However, others report that HBME-1 also shows immunoreactivity in follicular lesions such as follicular carcinomas, follicular adenomas, oncocytic tumors and hyperplasia (11,18).

When compared for HBME-1 staining, we found focal staining in 12.5% of follicular tumors and diffuse staining in 40% of PTC cases in our study. There was a statistically significant difference between follicular tumors and PTC-1 for HBME-1 staining ($p=0.005$). HBME-1 was seen to show basolateral membranous staining in PTC, consistent with literature data, while the staining in the follicular tumor group was negative and accepted as negative (6,10,11). No statistical study was performed as the staining feature was deemed to be inappropriate for statistical analysis.

Various studies have reported no p63 staining or rare weak staining in normal thyroid tissue and non-PTC lesions while PTC cases frequently show areas of focal staining with high specificity (4,28). Although most other studies report nuclear staining with p63 (4,13,16), a study with meningiomas has reported nuclear and cytoplasmic staining in grade II and grade III meningiomas (29).

We found focal nuclear and cytoplasmic p63 staining in 7.5% of follicular tumors and 37.5% of PTC cases. Focal p63 staining was present in 82% of classic PTC and 50%

of follicular variant cases with a general figure of 70% for PTC while follicular tumors showed weak staining at a rate of 20% (28). Our staining rate in PTC is lower than that in the literature but we found a statistically significant difference between follicular tumors and PTC cases for p63 expressions ($p=0.0001$). Taking our results and literature data into account, we feel that P63 may be an additional marker for PTC.

We believe that CD56 is not a reliable marker in the differentiation of PTC and follicular tumors but more extensive studies are needed on the subject. A detailed investigation of as many samples and sections as possible is suggested in cases with a histological suspicion of malignancy where the diagnosis is reached only by immunohistochemical tests (30). However, we think that HBME-1 is not adequate in differentiating follicular variant PTC from other follicular tumors by itself and that p63 may be added to the commonly-used HBME-1, CK19 and galectin panel.

ACKNOWLEDGEMENT

This study has been supported by the Dicle University Research Commission.

REFERENCES

1. **DeLellis R A, Williams ED:** Tumors of the thyroid and parathyroid. In DeLellis RA, Lloyd RV, Heitz PU, Eng C (Eds): WHO classification of tumours. Pathology & Genetics Tumors of Endocrine Organs. Lyon, IARC, 2004, 49-133
2. **Maitra A:** The Endocrine System. In Kumar V, Abbas AK, Fausto N, Aster JC (Eds): Robbins and Cotran Pathologic Basis of Disease. 8th ed., China, Elsevier Saunders, 2009, 1107-1130
3. **Li Volsi VA, Albores-Saavedra J, Asa SL, Baloch ZW, Sobrinho-Simoes M, Wenig B:** Papillary carcinoma. In DeLellis RA, Lloyd RV, Heitz PU, Eng C. (Eds): WHO classification of tumours. Pathology & Genetics Tumors of Endocrine Organs. Lyon, IARC, 2004, 57-66
4. **El Demellawy D, Nasr A, Alowami S:** Application of CD56, P63 and CK19 immunohistochemistry in the diagnosis of papillary carcinoma of thyroid. Diagnostic Pathology 2008, 3: 5.
5. **Casey MB, Lohse CM, Lloyd RV:** Distinction between papillary thyroid hyperplasia and papillary thyroid carcinoma by immunohistochemical staining for cytokeratin 19, galectin-3 and HBME-1. Endocr Pathol 2003, 14: 55-60
6. **Herrmann ME, LiVolsi VA, Pasha TL, Roberts SA, Wojcik EM, Baloch ZW:** Immunohistochemical expression of galectin-3 in benign and malignant thyroid lesions. Arch Pathol Lab Med 2002, 6: 710-713
7. **Soda G, Antonaci A, Bosco D, Nardoni S, Melis M:** Expression of bcl-2, c-erbB-2, p53 and p21 (waf1-cip1) protein in thyroid carcinomas. J Exp Clin Cancer Res 1999, 3: 363-367
8. **Zeromski J, Lawniczak M, Galbas K, Jenek R, Golusiński P:** Expression of CD56/ N-CAM antigen and some other adhesion molecules in various human endocrine glands. Folia Histochem Cytobiol 1998, 36:119-125
9. **Cavallaro U, Niedermeyer J, Fuxa M, Christofori G:** N-CAM modulates tumour-cell adhesion to matrix by inducing FGF-receptor signaling. Nat Cell Biol 2001, 3: 650-657
10. **Cheung CC, Ezzat S, Freeman JL, Rosen IB, Asa SL:** Immunohistochemical diagnosis of papillary thyroid carcinoma. Mod Pathol 2001, 14: 338-342
11. **Volante M, Bozzalla-Cassione F, DePompa R, Saggiorato E, Bartolazzi A, Orlandi F, Papotti M:** Galectin-3 and HBME-1 expression in oncocytic cell tumors of the thyroid. Virchows Arch 2004, 445: 183-188
12. **Ordóñez NG:** Application of mesothelin immunostaining in tumor diagnosis. Am J Surg Pathol 2003, 27: 1418-1428
13. **Kurita T, Medina RT, Mills AA, Cunha GR:** Role of p63 and basal cells in prostate. Development 2004, 131: 4955-4964
14. **Moll UM, Slade N:** p63 and p73: roles in development and tumor formation. Mol Cancer Res 2004, 2: 371-386
15. **Malaguarnera R, Mandarino A, Mazzon E, Vella V, Gangemi P, Vancheri P, Vigneri P, Aloisi A, Vigneri R, Frasca F:** The p53-homologue p63 may promote thyroid cancer progression. Endocr Relat Cancer 2005, 12: 953-971
16. **Di Como CJ, Urist MJ, Babayan I, Drobnjak M, Hedvat C, Teruya-Feldstein J, Pohar K, Hoos A, Cordon-Cardo C:** p63 expression profiles in human normal and tumor tissues. Clin Cancer Res 2002, 8: 494-501
17. **Signoretto S, Waltregny D, Dilks J, Isaac B, Lin D, Garraway L, Yang A, Montironi R, McKeon F, Loda M:** p63 is a prostate basal cell marker and is required for prostate development. Am J Pathol 2000, 157: 1769-1775
18. **Mase T, Funahashi H, Koshikawa T, Imai T, Nara Y, Tanaka Y, Nakao A:** HBME-1 immunostaining in thyroid tumors especially in follicular neoplasm. Endocr J 2003, 50: 173-177
19. **Levrero M, De Laurenzi V, Costanzo A, Gong J, Wang JY, Melino G:** The p53/p63/ p73 family of transcription factors: overlapping and distinct functions. J Cell Sci 2000, 113: 1661-1670
20. **Reis-Filho JS, Schmitt FC:** Taking advantage of basic research: p63 is a reliable myoepithelial and stem cell marker. Adv Anat Pathol 2002, 9: 280-289
21. **Lloyd RV, Erickson LA, Casey MB, Lam KY, Lohse CM, Asa SL, Chan JK, DeLellis RA, Harach HR, Kakudo K, LiVolsi VA, Rosai J, Sebo TJ, Sobrinho-Simoes M, Wenig BM, Lae ME:** Observer variation in the diagnosis of follicular variant of papillary thyroid carcinoma. Am J Surg Pathol 2004, 28: 1336-1340
22. **Hirokawa M, Carney JA, Goellner JR, DeLellis RA, Heffess CS, Katoh R, Tsujimoto M, Kakudo K:** Observer variation in encapsulated follicular lesions of the thyroid gland. Am J Surg Pathol 2002, 26: 1508-1514
23. **Migita K, Eguchi K, Kawakami A, Ida H, Fukuda T, Kurata A, Ishikawa N, Ito K, Nagataki S:** Detection of Leu-19 (CD56) antigen on human thyroid epithelial cells by an immunohistochemical method. Immunology 1991, 72: 246-249
24. **Zeromski J, Biczysko M, Stajgis P, Lawniczak M, Biczysko W:** CD56 (NCAM) antigen in glandular epithelium of human thyroid: light microscopic and ultrastructural study. Folia Histochem Cytobiol 1999; 37: 11-17
25. **Scarpino S, Di Napoli A, Melotti F, Talerico C, Cancrini A, Ruco L:** Papillary carcinoma of the thyroid: low expression of NCAM (CD56) is associated with downregulation of VEGF-D production by tumour cells. J Pathol 2007, 212 :411-419

26. **Scognamiglio T, Hyjek E, Kao J, Chen YT:** Diagnostic usefulness of HBME1, galectin-3, CK19 and CITED1 and evaluation of their expression in encapsulated lesions with questionable features of papillary thyroid carcinoma. *Am J Clin Pathol* 2006, 126: 700-708
27. **de Matos PS, Ferreira AP, de Oliveira Facuri F, Assumpção LV, Metzke K, Ward LS:** Usefulness of HBME-1, cytokeratin 19 and galectin-3 immunostaining in the diagnosis of thyroid malignancy. *Histopathology* 2005, 47: 391-401
28. **Unger P, Ewart M, Wang BY, Gan L, Kohtz DS, Burstein DE:** Expression of p63 in papillary thyroid carcinoma and in Hashimoto's thyroiditis: a pathobiologic link? *Hum Pathol* 2003, 34:764-769
29. **Rushing EJ, Olsen C, Man YG:** Correlation of p63 immunoreactivity with tumor grade in meningiomas. *Int J Surg Pathol* 2008, 16:38-42
30. **Yeğen G, Demir MA, Ertan Y, Nalbant OA, Tunçyürek M:** The role of the immunohistochemistry in differential diagnosis of follicular patterned lesions of thyroid. *Türk Patoloji Dergisi* 2009, 25:90-99