



Cytohistopathological Correlation of a Case of Squamous Cell Carcinoma of Gallbladder with Lymph Node Metastasis

Lenf Nodu Metastazlı Bir Safra Kesesi Skuamöz Hücreli Karsinomu Olgusunda Sitohistopatolojik Korelasyon

Indranil CHAKRABARTI¹, Amita GIRI¹, Nilanjana GHOSH²

Department of ¹Pathology and ²Community Medicine, North Bengal Medical College, WEST BENGAL, INDIA

ABSTRACT

Primary carcinomas of the gallbladder are rare malignancies and adenocarcinoma is the more common subtype. Primary squamous cell carcinoma of the gallbladder has rarely been diagnosed by aspiration cytology. Here, we present a case of a 62-year old female patient suffering from abdominal complaints who underwent ultrasound-guided fine-needle aspiration cytology and was diagnosed as keratinizing squamous cell carcinoma of gallbladder. The diagnosis was confirmed on subsequent histopathological examination that also revealed metastasis in the cystic lymph node. Histogenesis and biological behavior of squamous cell carcinoma of gallbladder remains a matter of debate but the role of aspiration cytology in diagnosing these lesions cannot be undermined.

Key Words: Squamous cell carcinoma, Gallbladder, Fine-needle aspiration, Lymph node, Metastasis

ÖZ

Safra kesesinin primer karsinomları nadir malignansilerdir ve adenokarsinom en sık görülen alt tiptir. Safra kesesinin primer skuamöz hücreli karsinomuna aspirasyon sitolojisiyle nadiren tanı konmuştur. Burada abdominal şikayetlerle gelen, ultrason rehberliğinde ince iğne aspirasyon sitolojisi yapılan ve safra kesesinin keratinize skuamöz hücreli karsinomu tanısı konan, 62 yaşında bir kadın hasta sunuyoruz. Tanı daha sonra histopatolojik incelemeyle doğrulandı. Ayrıca kistik lenf düğümünde metastaz da saptandı. Safra kesesinin skuamöz hücreli karsinomunun histogenezi ve biyolojik davranışı tartışmalıdır ama bu lezyonlara tanı koymakta aspirasyon sitolojisinin rolünün önemi inkar edilemez.

Anahtar Sözcükler: Skuamöz hücreli karsinom, Safra kesesi, İnce iğne aspirasyonu, Lenf nodu, Metastaz

INTRODUCTION

Primary carcinoma of the gallbladder is an uncommon malignancy but is on the rise in various parts of the world including India. Recent data suggests that in our country, the estimated number of gallbladder cancer during 2001 was 14,986 and the number is likely to increase to 23,750 by the year 2016 (1). The most common histological subtype is adenocarcinoma of gallbladder while squamous cell carcinomas are very rare with incidence ranging from 0 to 12.7% in various studies (2). The figure, however, appears erroneous with adenosquamous carcinomas, mucoepidermoid carcinomas, poorly differentiated carcinomas etc. getting wrongly categorized as squamous cell carcinomas (SCC) (3). SCCs usually behave aggressively with extension to liver and they rarely metastasize to lymph nodes. Here, we report a rare case of a SCC diagnosed

by fine needle aspiration cytology (FNAC) in which the subsequent histopathology showed a well-differentiated SCC with metastasis to the cystic lymph node.

CASE REPORT

A 62-year old female patient presented to the surgical outpatient department with complaints of anorexia and occasional pain in the right hypochondrium for the last month. On examination, the patient was pale but non-icteric with a body weight of 40 kg. On deep palpation, there was a small palpable lump in the right hypochondrium that was mildly tender. Her routine blood tests showed a hemoglobin level of 9.0 gm/dl with an ESR of 40 mm in the 1st hour. The peripheral blood smear showed predominantly normocytic, normochromic red blood cells (RBCs) with a population of microcytes as well. The liver function tests were all within normal limits except a mild elevation in

(*Türk Patoloji Derg* 2014, 30:81-84)

Received : 11.10.2011 Accepted : 14.02.2012

Correspondence: Indranil CHAKRABARTI

North Bengal Medical College, Department of Pathology,
WEST BENGAL, INDIA

E-mail: drinch@rediffmail.com Phone: +91 332 416 15 97

alkaline phosphatase (320 IU/L). An ultra sonogram showed a gallbladder mass with biliary sludge in the lumen. There was no discernible adhesion with the adjacent liver and no other lesion was seen in the liver. An ultrasound-guided fine-needle aspiration (US-FNA) was done with a 24-gauge needle fitted to 10 cc syringe, from the gallbladder mass. The alcohol-fixed smears were stained with Papanicolaou stain and the air-dried smears with May-Grunwald-Giemsa (MGG) stain. The cellular smears showed presence of keratinized, malignant looking squamous epithelial cells with nuclear pyknosis, hyperchromasia, pleomorphism and membrane irregularity (Figures 1 A, B). The background was dirty with presence of keratinous material and cell debris.

A cytological diagnosis of SCC of gallbladder was given with an advice of urgent histopathological examination. The patient was operated one-month following the cytological diagnosis. A cholecystectomy along with a wedge resection of the adjacent liver tissue was done. A single 1 cm diameter cystic lymph node seen preoperatively was also resected. The entire specimen was sent to the pathology department for histopathological examination. Grossly, the gallbladder was partially cut open and measured about 8X3 cm with a wall thickness varying from 0.5 cm to 3.0 cm. There was presence of an irregular cauliflower-like mass measuring 4X3 cm (Figure 2). The rest of the mucosa was ulcerated. There was some amount of biliary sludge.

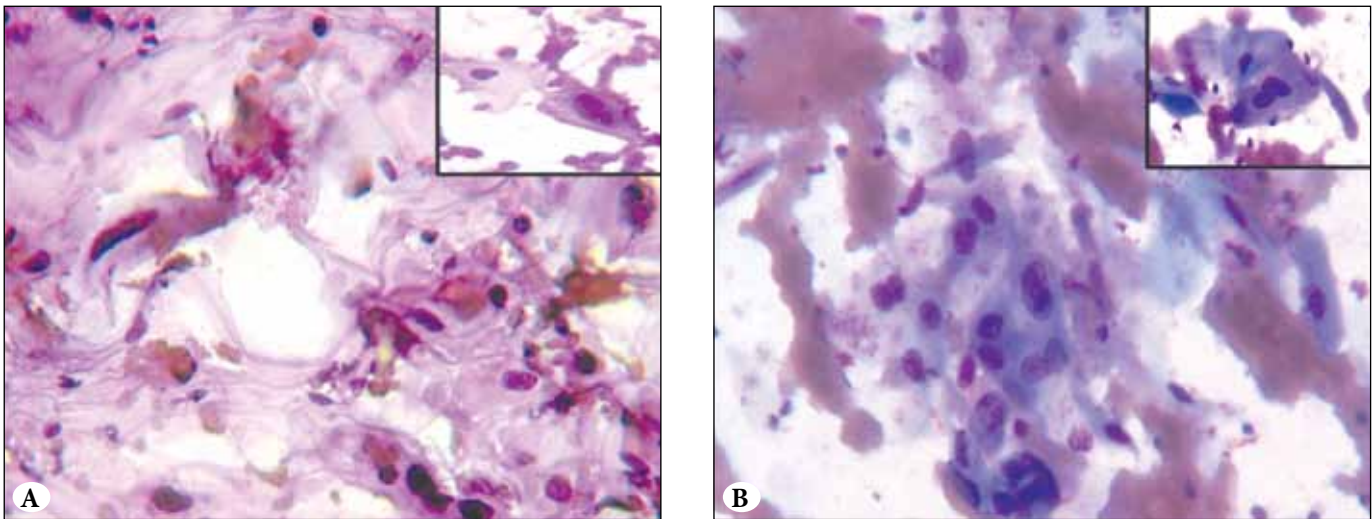


Figure 1: Microphotograph showing malignant looking squamous cells and keratinous material in a necro-hemorrhagic background. (A) Papanicolaou; x400, (B) MGG x400) Inset showing atypical squamous cells in greater detail.

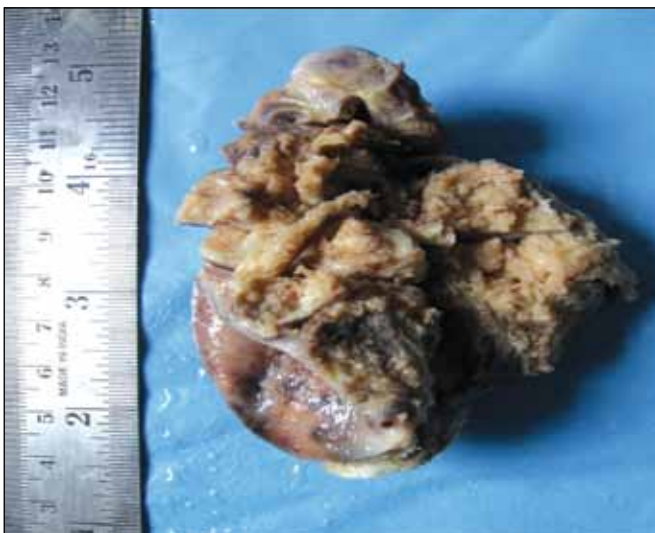


Figure 2: Resected specimen of gallbladder showing the cauliflower-like mass.

The adjacent liver bed appeared brownish and irregular. A small 0.8 cm lymph node labeled as cystic lymph node was sent in a separate container. Several sections were taken from the mass as well as the apparently uninvolved gallbladder. The lymph node was subjected to tissue processing in entirety. The histopathological examination showed presence of a keratinizing SCC with areas of necrosis (Figure 3A) and invasion up to the outer muscle layer but not reaching the serosa. There was an area showing perineural invasion by tumor cells. The adjacent liver bed was free of tumor cells. The rest of the mucosa was ulcerated. Following the diagnosis, the entire gallbladder was processed and subjected to histopathological examination. Even on sampling the entire specimen, we could not get any foci of adenocarcinoma. There was only a single focus showing the normal looking gallbladder epithelium abruptly giving way to the SCC (Figure 3B). The section from the lymph

node showed metastatic deposits of SCC (Figure 3C). A final diagnosis of pure SCC of gallbladder with metastasis to cystic lymph node was made. The patient refused any further treatment in the hospital and was discharged on request. Unfortunately the patient was lost to follow-up.

DISCUSSION

Primary squamous cell carcinomas (SCC) are rare entities with an overall incidence of 0 to 12.7% (2). However, if we can carefully exclude other types of carcinomas misdiagnosed as or mixed with squamous cell carcinomas, the incidence of pure SCCs drops down to 0 to 3.3% of all gallbladder cancers (4,5,6). SCC of the gallbladder usually occur in the fourth to sixth decade of life with a male: female ratio of 3:1 (3,7). They have been associated with rapid growth, widespread infiltration and metastasis (2,8), but the fact appears to be confounded by the inclusion of adenosquamous carcinoma cases as well (2). Pure SCCs are usually characterized by localized growth and lack or rarity of lymph node involvement and no visceral metastasis (2,3,4). Since there is no squamous lining in the gallbladder, SCC in the gallbladder may arise from heterotopic squamous epithelium, malignant transformation of metaplastic squamous epithelium or from squamous metaplasia of adenocarcinoma (3,8). Since there is no conclusive proof of heterotopic squamous epithelium, the other two possibilities are more probable (7). Muto *et al* in their study of 1,000 resected gallbladders did not find any evidence of squamous metaplasia in gallbladder. They hypothesized that the malignant process starts as adenocarcinoma, and then squamous metaplasia of adenocarcinoma occurs after which the squamous cell carcinoma overgrows the adenocarcinoma part to form a pure SCC (9). In our case, we found the normal columnar epithelium of gallbladder directly adjacent to squamous epithelium giving way to squamous cell carcinoma with no intervening foci of adenocarcinoma. We also found foci showing the surface epithelium of gallbladder being lined by squamous epithelium leading to SCC (Figure 3A-C). The surgical options of SCC of gallbladder consist of cholecystectomy with resection of a wedge of adjacent liver tissue or direct liver resection along with regional lymphadenectomy and skeletization of the hepatic hilum (3,10). Cytologic diagnosis of gallbladder malignancies by FNA has become common due to accessibility of imaging techniques like ultrasound (US) and computed tomography (CT). However, the diagnosis of SCC by FNAC is rare with 2 cases reported by Gupta *et al* (11). In a study of 82 cases of US-FNAC, Das *et al* (12) described 12.5% cases of squamous and adenosquamous carcinomas.

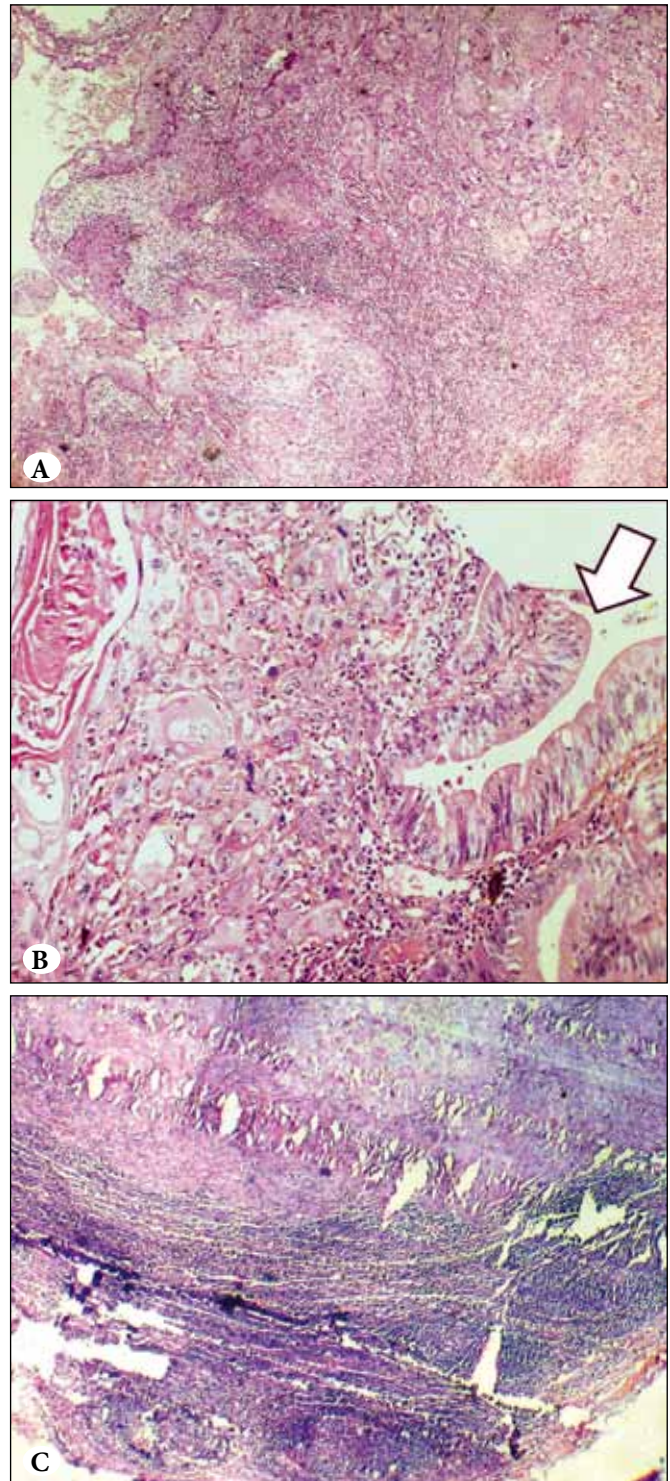


Figure 3: (A) Microphotograph showing a well - differentiated squamous cell carcinoma of gallbladder, the surface lining being replaced by squamous epithelium (H&E; x400), (B) Microphotograph showing normal columnar gallbladder epithelium (white arrow) giving way to the squamous cell carcinoma. (H&E; x400), (C) Microphotograph showing metastatic deposits of squamous cell carcinoma in cystic lymph node (H&E; x400).

Here, we describe an extremely rare case of pure well-differentiated SCC of gallbladder diagnosed by FNAC. The lymph node metastasis in this case of SCC of gallbladder was another interesting finding that is not described in literature. The adjacent liver tissue was not involved in the resected specimen. The extent of the tumor at the time of diagnosis is the most important determinant of survival and the majority of the patients die around six months after diagnosis when radical surgery is not performed (3,7,10,13). However, our patient refused any chemo-radiotherapy and also did not turn up for follow-up.

In conclusion, the histogenesis of SCC in gallbladder has been an enigma for years. Our case suggests that squamous metaplasia followed by dysplasia may ultimately give rise to SCC of gallbladder and reemphasizes the fact that imaging assisted FNAC of gallbladder mass appears to be an important tool in diagnosing these rare tumors with sufficient accuracy.

REFERENCES

1. Murthy NS. Trends and Patterns of Cancer Load in India: An Epidemiological Estimation and Analysis. Report of an ICMR Study. Indian Council of Medical Research, New Delhi, 2009.
2. Roppongi T, Takeyoshi I, Ohwada S, Sato Y, Fujii T, Honma M, Morishita Y. Minute squamous cell carcinoma of the gallbladder: A case report. *Jpn J Clin Oncol.* 2000;30:43-5.
3. Karasawa T, Itoh K, Komukai M, Ozawa U, Sakurai I, Shikata T. Squamous cell carcinoma of gallbladder-report of two cases and review of literature. *Acta Pathol Jpn.* 1981;31:299-308.
4. Kumar A, Singh MK, Kapur BML. Synchronous double malignant tumors of the gall bladder. A case-report of squamous cell carcinoma with an angiosarcoma. *Eur J Surg Oncol.* 1994;20: 63-7.
5. Piehler JM, Crichlow RW. Primary carcinoma of the gall bladder. *Surg Gynecol Obstet.* 1978;147: 929-42.
6. Dowling GP, Kelly JK. The histogenesis of adenocarcinoma of the gallbladder. *Cancer.* 1986;58:1702-8.
7. Hanada M, Shimizu H, Takami M. Squamous cell carcinoma of the gallbladder associated with squamous metaplasia and adenocarcinoma in situ of the mucosal columnar epithelium. *Acta Pathol Jpn.* 1986;36:1879-86.
8. Edmondson HA. Tumors of the Gallbladder and Extrahepatic Bile Ducts. In: Atlas of Tumor Pathology, Fasc. 26. Washington, DC: Armed Forces Institute of Pathology; 1967. 26-66.
9. Muto Y, Uchimara M, Waki S, Hayashi T, Samejima K, Okamoto K. Clinicopathologic study of adenosquamous carcinoma of the gall bladder and bile duct. *Jpn J Cancer Clin.* 1982;28:440-4.
10. Miyazaki K, Tsutsumi N, Kitahara K, Mori M, Sasatomi E, Tokunaga O, Hisatsugu T. Hepatopancreatoduodenectomy for squamous and adenosquamous carcinoma of the gallbladder. *Hepato-Gastroenterol.* 1995;42:47-50.
11. Gupta RK, Naran S, Lallu S, Fauck R, elAnsari A. Fine needle aspiration cytodiagnosis of primary squamous cell carcinoma of the gallbladder. Report of two cases. *Acta Cytol.* 2000;44:467-71.
12. Das DK, Tripathi RP, Bhambhani S, Chachra KL, Sodhani P, Malhotra V. Ultrasound- guided fine-needle aspiration cytology diagnosis of gallbladder lesions: A study of 82 cases. *Diagn Cytopathol.* 1998;18:258-64.
13. Khaira HS, Awad RW, Thompson AK. Squamous cell carcinoma of the gallbladder presenting with a biliary-colic fistula. *Eur J Surg Oncol.* 1995;21:581-2.