

Malignant Melanoma Presenting as a Mediastinal Mass- A Primary or Metastatic Melanoma of Unknown Primary Origin?

Mukta PUJANI¹, Mohd Jaseem HASSAN¹, Sujata JETLEY¹, Prabhat Kumar RAINA², Mukesh KUMAR³

Department of ¹Pathology, ²Surgery, and ³Radiology, Hamdard Institute of Medical Sciences & Research, NEW DELHI, INDIA

ABSTRACT

The most common site of primary malignant melanoma is the skin, however, virtually any organ system may be involved. Metastatic melanoma of unknown primary origin accounts for approximately 2-6% of all melanoma cases. The mediastinum as the site for malignant melanoma is extremely rare, both as a primary or metastatic lesion. Primary malignant melanoma of mediastinum is very rare with only a handful of reports in the literature. We hereby report a rare case of malignant melanoma of mediastinum in a 31 year old male who was initially misdiagnosed on fine needle aspiration cytology as adenocarcinoma for which he received chemotherapy with clinical deterioration. Even on extensive meticulous search, no primary was discovered.

Key Words: Malignant melanoma, Neoplasm of unknown primary, Mediastinal neoplasm

INTRODUCTION

Primary Malignant melanoma (MM), although predominantly a tumor of skin, can occur at almost any site in the body where nevus cells/ melanocytes are found. Moreover, MM has a very high tendency for metastasis. Metastatic melanoma of unknown primary origin (MUP) accounts for approximately 2-6% of all melanoma cases (1). Mediastinum as the site for MM is extremely rare, both as a primary or a metastatic lesion. On search of literature, we came across a limited number of reports of mediastinal malignant melanoma (2-6). To label a melanoma as MUP, thorough history, physical examination and extensive investigative workup is required to exclude a primary MM. We hereby report a rare case of MM of mediastinum in a 31-year-old male in whom no primary was discovered even after meticulous search.

CASE REPORT

A 31-year-old male presented with dry cough and chest pain associated with weight loss. Six months back the patient was investigated for similar complaints and a right parahilar mass measuring 8x6cm was detected in the anterior mediastinum. Computed tomography guided fine needle aspiration cytology (FNAC) performed at a private centre was suggestive of adenocarcinoma. The patient was given 6 cycles of chemotherapy (paclitaxel and carboplatin) but did not show any symptomatic improvement and then presented to our hospital.

On examination, the patient was of average build with no lymphadenopathy, pallor, icterus or cyanosis. A contrast-enhanced computed tomography (CECT) of the thorax and abdomen was performed and revealed a large, irregular, heterogeneously-enhancing soft tissue density mass lesion in the anterior mediastinum, predominantly on the right side. The lesion measured 10.7 x 9.9 x 10.7 cm and showed necrotic areas with few foci of calcification with extension from the level of the arch of aorta superiorly to the level of the diaphragm (Figure 1). The rest of the visceral organs were unremarkable. Levels of tumor markers like carcinoembryonic antigen, CA 19.9, alphafetoprotein and beta-human chorionic gonadotrophin were within the normal range. A Tru-cut biopsy was performed from the mediastinal mass.

Microscopically, the tumor was composed of round to oval cells with moderate amount of cytoplasm with melanin pigment in many cells. Nuclei were moderately pleomorphic with coarse chromatin and inconspicuous nucleoli (Figure 2). Mitotic rate was 5-6/10 high power fields. Focal areas of necrosis were also observed. Possibility of malignant melanoma was suggested. Immunohistochemistry revealed positive immunostaining for vimentin, HMB-45, S-100 while negative results were obtained with cytokeratin and CD 45. Neuroendocrine markers like neuron specific enolase (NSE) and chromogranin were also negative. A final diagnosis of malignant melanoma was established.

(*Turk Patoloji Derg* 2017, 33:168-170)

Received : 02.09.2014 Accepted : 16.10.2014

Correspondence: Sujata JETLEY

Department of Pathology, Hamdard Institute of Medical Sciences & Research, NEW DELHI, INDIA

E-mail: drjetley2013@gmail.com Phone: +91 935 062 16 81

A meticulous search for primary was conducted through examination of the entire skin, eye, genitalia and anal canal. There was no history of any prior surgical resection of a mole. Chest X-ray and thoracic and abdominal CECT did not reveal any lesion in any of the visceral organs. Upper gastrointestinal tract endoscopy and rectosigmoidoscopy were also performed and were within normal limits. A diagnosis of melanoma of unknown primary was therefore established.

The mass was large and unamenable to surgical resection. The option of chemotherapy was not explored as the patient had not responded to chemotherapy given prior to biopsy and MM is not a chemosensitive disorder. The patient was put on immunotherapy with close follow-up. CT scan performed three months later showed a large space-occupying lesion in the liver. The patient expired one month thereafter.

DISCUSSION

Malignant melanoma accounts for 1.5% of all cancers with increasing prevalence over the last decade. The most common site of primary MM is the skin but virtually any organ system where melanocytes/nevus cells may be encountered can become involved. Although primary MM has been reported in the bronchus, brain, gastrointestinal tract and rectum, melanomas at sites other than skin are usually secondary deposits. This is due to a high tendency of melanomas to metastasize (3).

The mediastinum as a site for malignant melanoma is extremely unusual either as a metastatic deposit or as a primary. Primary MM of the mediastinum is very rare with only a handful of reports in the literature (2-6). The differential diagnoses for melanotic tumors of the mediastinum include pigmented extra adrenal paraganglioma, pigmented carcinoid tumor of thymus, melanotic schwannoma, melanotic neuroectodermal neoplasm and primary

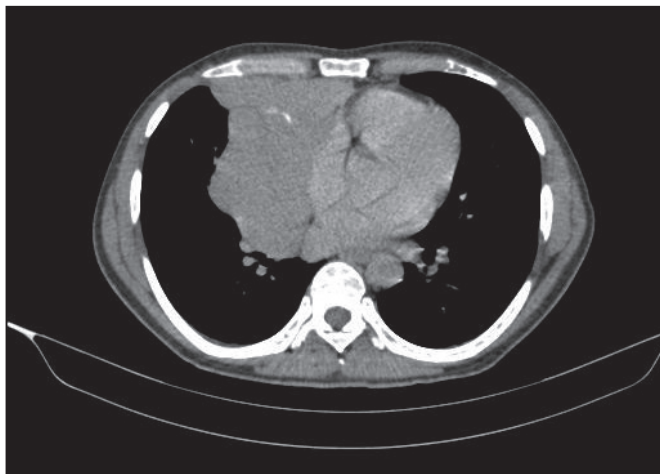


Figure 1: Chest CT revealed a large, irregular heterogeneously-enhancing soft tissue density mass lesion in the anterior mediastinum, predominantly on right side.

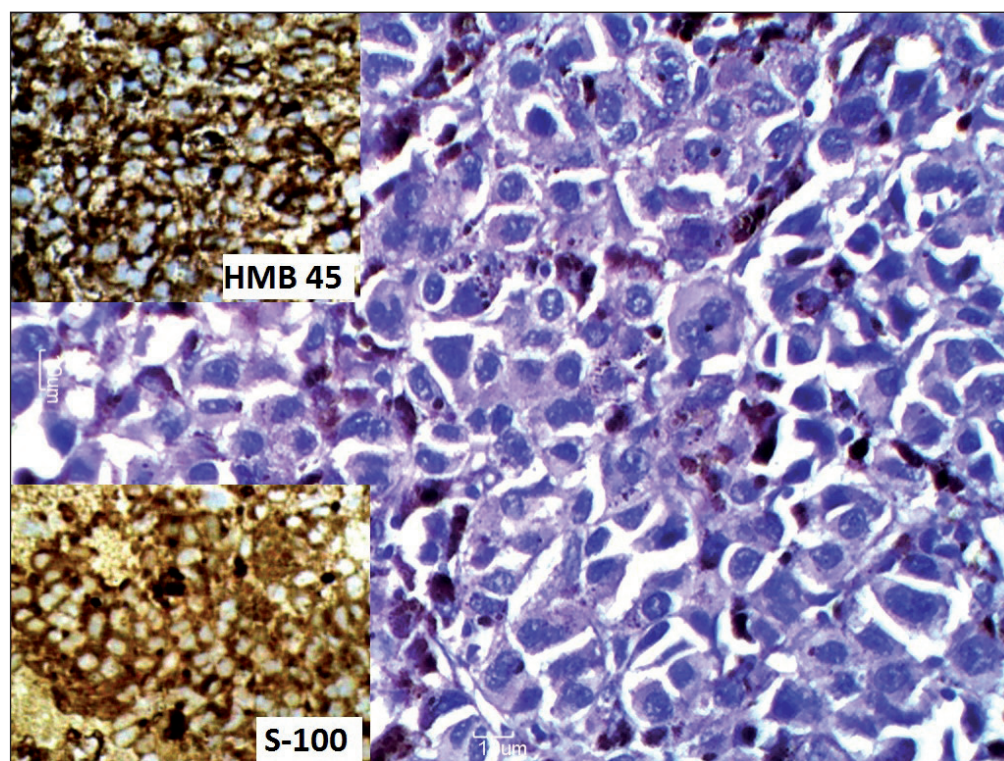


Figure 2: Photomicrograph showing round to oval tumor cells with moderate amount of cytoplasm with melanin pigment in many and moderately pleomorphic nuclei with coarse chromatin (H&E; x400); inset top left immunohistochemistry for HMB 45 was positive, inset bottom left immunohistochemistry for S-100 was positive.

MM (5). Melanotic schwannoma and MM can not be distinguished even on immunohistochemistry as both are strongly positive for S-100, HMB-45 and melan A. The light microscopic features favouring melanotic schwannoma include circumscription without encapsulation, high cellularity, a predominance of spindle cells, which are heavily pigmented and arranged in whorls or palisades and a lack of cytological atypia or mitoses, contrary to the findings in the present case (7).

The diagnosis of pigmented extra adrenal paraganglioma is supported by an organoid or zellballen pattern and positivity for S-100, NSE, chromogranin and synaptophysin. Absence of these features helped in ruling out this entity in our case. Melanotic neuroectodermal neoplasm is characterised by an admixture of large melanocyte like cells and smaller neuroblast like cells, infrequent mitoses and positivity for cytokeratin, NSE, HMB-45 and S-100 on immunohistochemistry.

When the site of origin of a histologically documented carcinoma is not identified clinically, this is referred to as carcinoma of unknown primary origin or occult primary malignancy. The majority of cases of carcinoma of unknown primary are adenocarcinomas or undifferentiated tumors; less commonly, squamous cell carcinoma, melanoma, sarcoma, and neuroendocrine tumors are seen. In approximately 15% to 25% of patients, the primary site cannot be identified even at postmortem examination (8). Metastatic melanoma arising from unknown primary origin was first described in 1952 (9). MUP accounts for 2-6% of all melanomas. These may be seen as subcutaneous nodules or lymph node metastases. Very rarely, simultaneous visceral metastasis may be detected at diagnosis (1).

MUP can be explained by the following hypothesis: 1- De novo melanoma can originate from malignant transformation of ectopic melanocytes/ nevus cells; 2- Complete regression of the primary melanoma after metastasis has taken place (10).

MUP were extensively studied for the first time by Das Gupta et al. (11) in 47 patients from a total of 992 melanoma cases (3.7%). They laid down certain criteria for the diagnosis of MUP: 1- Normal findings on eye, rectum and genital region examination, 2- the following should be excluded: history of orbital enucleation, any previous surgery for skin lesions like nevus etc., especially in a region of skin with drainage to the involved lymph nodes.

Schlagenhauff et al. (1) gave recommendations for initial staging examinations in patients with MUP. According to them, initial search for the primary should be restricted to an inspection of entire skin surface and adjacent mucosa

as well as detailed examination of the areas drained by involved lymph nodes. Chest X ray / computed tomography (CT), abdominal ultrasound (USG) / CT, USG of regional lymph nodes and CT / magnetic resonance imaging (MRI) of brain were generally recommended in all cases of MUP. Further specific investigations were indicated depending upon the location of MUP.

When corresponding stages were compared, the survival of patients with melanoma of unknown primary was found to be similar to that of patients with known primary (12). On the contrary, Schlagenhauff et al. (1) observed a surprisingly high 5 year survival rate of 83% in patient with stage IIIa disease. However, unfavourable prognosis was observed in patients with stage IV disease and MUP.

REFERENCES

- Schlagenhauff B, Stroebel W, Ellwanger U, Meier F, Zimmermann C, Breuninger H, Rassner G, Garbe C. Metastatic melanoma of unknown primary origin shows prognostic similarities to regional metastatic melanoma: Recommendations for initial staging examinations. *Cancer*. 1997;80:60-5.
- Lau C, Bentley R, Gockerman J, Que L, D'Amico T. Malignant melanoma presenting as a mediastinal mass. *Ann Thorac Surg*. 1999;67:851-2.
- Karuppiyah SV, Buchan KG. Primary malignant melanoma: A rare cause of mediastinal mass. *Jpn J Thorac Cardiovasc Surg*. 2006;54:396-8.
- Takao H, Shimizu S, Doi I, Watanabe T. Primary malignant melanoma of the anterior mediastinum: CT and MR findings. *Clin Imaging*. 2008;32:58-60.
- Kalra A, Kalra A, Palaniswamy C, Gajera M, Rajput V. Primary malignant melanoma presenting as superior mediastinal mass. *International Journal of Surgery Case Reports*. 2011;2:239-40.
- Park SY, Kim MY, Chae EJ. Primary malignant melanoma of the mediastinum: Radiologic and pathologic correlation in two case. *Korean J Radiol*. 2012;13:823-6.
- Torres-Mora J, Dry S, Li X, Binder S, Amin M, Folpe AL. Malignant melanotic schwannian tumor: A clinicopathologic, immunohistochemical, and gene expression profiling study of 40 cases, with a proposal for the reclassification of "melanotic schwannoma". *Am J Surg Pathol*. 2014 ;38:94-105.
- Neumann KH, Nystrom JS. Metastatic cancer of unknown origin: Nonsquamous cell type. *Semin Oncol*. 1982;9:427-34.
- Cormier JN, Xing Y, Feng L, Huang X, Davidson L, Gershenwald JE, Lee JE, Mansfield PF, Ross MI. Metastatic melanoma to lymph node in patients with unknown primary sites. *Cancer*. 2006;106:2012-20.
- Clerico R, Bottoni U, Paolino G, Ambrifi M, Corsetti P, Devirgiliis V, Calvieri S. Melanoma with unknown primary: Report and analysis of 24 patients. *Med Oncol*. 2012;29:2978-84.
- Das Gupta T, Bowden L, Berg JW. Malignant melanoma of - unknown primary origin. *Surg Gynecol Obstet*. 1963;117:341-5.
- Giuliano AE, Moseley HS, Morton DL. Clinical aspects of an unknown primary melanoma. *Ann Surg*. 1980;191:98-104.